



Mondor's disease of penis: a forgotten disease

B Kumar, T Narang, B D Radotra and S Gupta

Sex. Transm. Inf. 2005;81:480-482
doi:10.1136/sti.2004.014159

Updated information and services can be found at:
<http://sti.bmj.com/cgi/content/full/81/6/480>

These include:

Rapid responses

You can respond to this article at:
<http://sti.bmj.com/cgi/eletter-submit/81/6/480>

Email alerting service

Receive free email alerts when new articles cite this article - sign up in the box at the top right corner of the article

Topic collections

Articles on similar topics can be found in the following collections

[Sexually Transmitted Infections](#) (1313 articles)

Notes

To order reprints of this article go to:
<http://www.bmjournals.com/cgi/reprintform>

To subscribe to *Sexually Transmitted Infections* go to:
<http://www.bmjournals.com/subscriptions/>

IN PRACTICE

Mondor's disease of penis: a forgotten disease

B Kumar, T Narang, B D Radotra, S Gupta

Sex Transm Infect 2005;**81**:480–482. doi: 10.1136/sti.2004.014159

Background: Mondor's disease of penis is an uncommon genital condition involving the penile sulcus in a circumferential manner. Although this disorder is almost always self limited, it is associated with considerable psychological stress and sexual disharmony.

Methods: All patients attending the sexually transmitted disease clinic during 1991–2003 were examined for evidence of Mondor's disease of penis. Detailed history and clinical findings were recorded in a specially designed proforma. Histopathological examination and staining with CD31 and CD34 monoclonal antibodies was also done in 11 patients.

Results: 18 out of 1296 patients attending the sexually transmitted diseases (STD) clinic during the study period were found to have penile Mondor's disease, giving an incidence of 1.39%. 17 patients had history of one or more episodes of STDs. Histopathological specimens showed prominent vessels with plump endothelial cells and thickened blood vessel walls. The occasional vessel showed complete occlusion of its lumen.

Conclusions: In our study we did not find any evidence of lymphatic involvement. Non-lymphatic vessels, mainly veins, were predominantly involved. In our opinion Mondor's phlebitis of penis or Mondor's disease of penis are better terms to describe the condition rather than non-venereal sclerosing lymphangitis.

Mondor's disease of penis is an uncommon genital condition presenting as a painless or tender cord-like lesion involving the coronal sulcus in a circumferential manner, or rarely the prepuce and the distal part of the penile shaft. The disorder was originally described by Hoffman¹ in 1923, who thought it to be "simulation of primary syphilis by gonorrhoeal lymphangitis." Subsequently various names have been used to describe it such as circular indurated lymphangitis, non-venereal sclerosing lymphangitis of the penis,² benign transient lymphangiectasis, and localised lymphoedema.³ Braun-Falco⁴ described for the first time the phlebitis of the dorsal vein of the penis and later it was termed Mondor's disease of the penis.⁵ The aetiopathogenesis of this disorder is still controversial as, on histopathology, lymphatic channels as well as non-lymphatic vessels have been equally incriminated.

Most of the studies in the past have reported only a few patients and information from India is scanty. So, this study was undertaken to evaluate Mondor's disease of penis in our sexually transmitted disease (STD) clinic attendees during past 13 years.

METHODS

All patients attending the STD clinic during 1991–2003 were examined for evidence of Mondor's disease of penis. Detailed history and clinical findings were recorded in a specially

designed proforma which included demographic and socio-economic data, as well as information on disease related factors like trauma, masturbation, sexual practices, contraceptive measures, and STDs. They were investigated for the presence of any STD by relevant investigations. Biopsy for histopathological examination was done in 11 patients. In addition to the routine haematoxylin and eosin staining the sections were also treated with CD31 and CD34 monoclonal antibodies. No treatments were recommended, although all the patients were told about the transient nature of the disease and reassured.

RESULTS

Eighteen of 1296 patients attending the STD clinic during the study period were found to have Mondor's disease of penis (incidence 1.39%). The age of the patients ranged from 18–45 years (mean 29.4 years). Three of these 18 patients were married. All the patients were uncircumcised. Duration of lesions at presentation varied from 1–4 weeks (mean 2.3 weeks).

Fifteen patients had one or more episodes of STDs in the past (table 1). The time between the episode of STD and their visit to the clinic varied from 4–12 weeks (mean 6.8 weeks). Two patients, one each with genital warts and chancroid, developed lesions while undergoing treatment.

The majority of the patients were asymptomatic; only six (33.3%) patients had mild to moderate pain during erection. Most of the patients became aware of the lesions during local cleansing, foreplay, or subsequent sexual activity. None of the patients experienced local oedema during onset or in the course of the disease. All the patients denied homosexual activity. The details of the sexual behaviour/attributes of the patients are given in table 2.

All the patients presented with subcutaneous, skin coloured, cord-like thickening on the penis. In 15 patients the lesions were parallel to the coronal sulcus (giving the appearance of a double coronal sulcus) (fig 1) and three patients had lesions in the midline over dorsum of penis. The

Table 1 Occurrence of past or present STIs

STD	No of patients with history of STI in the past	No of patients with coexistent STD and Mondor's disease of penis
Genital warts	6	1
Chancroid	2	1
Primary chancre	2	–
Secondary syphilis	2	–
Gonorrhoea	1	–
Non-gonococcal urethritis	1	–
Donovanosis	1	–
None	1	–

Abbreviations: STD, sexually transmitted diseases

Table 2 Sexual behaviours/attributes of patients

Sexual behaviour	No of patients
Contact with commercial sex worker	16
Unprotected sex	10
Use of sex stimulants (frequent)	14
Masturbation (daily)	12
History of vigorous sex after abstinence	17

lesions varied in size from 1–3 cm. Tenderness could be elicited in only two patients.

HIV serology was negative in all patients while VDRL was still reactive in two patients with a previous history of syphilis (1:2 and 1:4 dilutions). None of our patients had any other local or systemic diseases including diabetes mellitus or hypertension.

Histopathological study was carried out in 11 cases and all the specimens showed prominent vessels with plump endothelial cells, proliferation of connective tissue of the vessel wall, and partially granulating thrombus (fig 2). Veins were found to be sclerosed in six patients while one showed sclerosis of both arteries and veins. No pathology in lymphatics could be visualised in any of the specimens. Sparse perivascular cellular infiltrate composed of lymphocytes, histiocytes, and plasma cells was noticed in the dermis. The intimal layer and tunica media of blood vessels could be easily differentiated in seven specimens with elastic tissue stain (elastic Van Gieson). CD31 and CD34 monoclonal antibodies revealed endothelin staining in all these patients.

Spontaneous clearing of lesions occurred in all patients over a period of 4–8 weeks (mean 5.6 weeks). None had any recurrence of similar lesion over the 4–6 month follow up period.

DISCUSSION

Penile Mondor's disease is a benign pathology of the superficial dorsal penile vein affecting sexually active men.² In this study most of the subjects were young and under 45 years of age. Although lesions are classically asymptomatic, some patients have pain or discomfort, especially on erection.^{5–6} The majority of our patients were asymptomatic and only one third presented with mild to moderate pain and tenderness

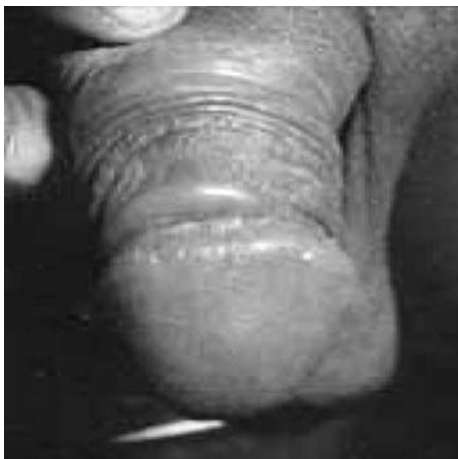

Figure 1 Mondor's disease of penis presenting as a firm, cord-like lesion of the coronal sulcus

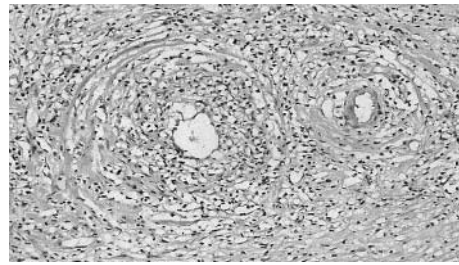


Figure 2 Section showing an arteriole and venule with plump endothelial cells and thickened blood vessel wall along with perivascular cellular infiltrate composed of lymphocytes, histiocytes, and plasma cells.

The cause of penile Mondor's disease remains unclear. Non-venereal causes such as enteroviral infection, irritation from menstrual blood, tuberculosis and circumferential scarring from circumcision have been suggested but there has been no clinical or investigational support.^{2–7} Mechanical trauma has been most frequently postulated theory.^{8–9} Patients have a history of increased sexual activity immediately before the appearance of the lesion. Usually the lesions occur shortly (24–48 hours) after sexual intercourse. The majority of the reports indicate that temporary abstinence results in prompt involution of lesions and return to sexual activity can lead to recurrence. Most of our patients had history of abstinence of few weeks because of the past STDs. However, absence of recurrence after resumption of the sexual activity indicates that trauma may not be the only factor or the different aetiological factors might result in a common response.

Various STDs have been associated with this condition.^{3–6} Although one fourth of the 105 previously reported cases have demonstrated a close temporal relation to STDs, it is difficult to determine whether these patients have a greater incidence of STDs than an otherwise analogous at-risk population or that frequent sexual activity exposes them to both the acquisition of an STD and development of Mondor's phlebitis.

Controversy regarding the lymphatic versus venous origin of this condition has been discussed in the literature.^{5–10–11} Lymphatics were not involved in any of our patients; the veins were predominantly involved which is in consonance in some of the previous studies.^{5–10–12} The striking feature noticed in all patients was plump endothelial cells (lymphatic vessels—flat endothelial cells). We could easily differentiate the intimal layer from connective tissue in the blood vessel lumen with elastic tissue stain (loss of differentiation between the intimal layer and connective tissue). The positive staining of vascular endothelial cells on staining with CD31 and CD34 monoclonal antibodies also hints towards a venous pathology. But anatomical and histological differentiation between the veins and lymphatic vessels of the penis can sometimes be difficult and this issue can only be settled by penile sonography with colour Doppler imaging³ and endothelin staining. In our opinion "Mondor's disease of penis" or "Mondor's phlebitis of penis" are better terms for description of the condition rather than non-venereal sclerosing lymphangitis.

Mondor's disease of penis is a rare condition often associated with significant morbidity and the attending physicians should be aware of this benign, self resolving condition to prevent misdiagnosis and overaggressive treatment with its attendant physical and emotional trauma. We believe proper explanation, strong reassurance, and temporary sexual abstinence should remain the mainstay of therapy, unless the disease is very symptomatic or the lesions persist for a longer than average healing time.

CONTRIBUTORS

BK, clinical evaluation; SG, clinical evaluation; TN, clinical evaluation and data analysis; BDR, histopathology and special staining.

Authors' affiliations

B Kumar, T Narang, S Gupta, Department of Dermatology, Venereology and Leprology, Postgraduate Institute of Medical Education and Research, Chandigarh, India

B D Radotra, Department of Pathology, Postgraduate Institute of Medical Education and Research, Chandigarh, India

Correspondence to: Dr Bhushan Kumar, Department of Dermatology, Venereology and Leprology, PGIMER, Chandigarh-160 012, India; kumarbhushan@hotmail.com

Accepted for publication 2 March 2005

REFERENCES

- Hoffmann E. Vortauschung primärer syphilis durch gonorrhoeische lymphangitis (gonorrhoeischer pseudoprimäraffekt). *Munch Med Wschr* 1923;**70**:1167–8.
- Nickel WR, Plumb RT. Nonvenereal sclerosing lymphangitis of the penis. *Arch Dermatol* 1962;**86**:761–3.
- McMillan A. Lymphocoele and localized lymphoedema of the penis. *Br J Vener Dis* 1976;**52**:409–11.
- Braun-Falco O. Sur Klinik, Histologie und Pathogenese der strangformigen, oberflächlichen phlebitiden. *Dermatol Wochenschr* 1955;**132**:705–15.
- Sasso F, Gulino G, Alcini TP. Penile Mondor's disease: an under estimated pathology. *Br J Urol* 1996;**77**:729–32.
- Von Berde K. Further contribution to the knowledge of the nonvenereal diseases: lymphangitis of the coronary sulcus. *Dermatol Wochenschr* 1937;**105**:1532–40.
- Broadus SB, Leadbetter GW. Surgical management of persistent, symptomatic nonvenereal sclerosing lymphangitis of the penis. *J Urol* 1982;**127**:987–8.
- Sieunarine K. Non-venereal sclerosing lymphangitis of the penis associated with masturbation. *Br J Urol* 1987;**59**:194–5.
- Lassus A, Niemi KM, Valle SL, et al. Sclerosing lymphangitis of the penis. *Br J Vener Dis* 1972;**48**:545–8.
- Aragona P, Piazza R, Artibani W, et al. The so-called Hoffman's lymphangitis of the penis: is it a lymphangitis or phlebitis? *Int Urol Nephrol* 1988;**20**:139–45.
- Findlay GH, Whiting DA. Mondor's phlebitis of the penis. A condition miscalled 'non-venereal sclerosing lymphangitis'. *Clin Exp Dermatol* 1977;**2**:65–7.
- Tanii T, Hamada T, Asai, et al. Mondor's phlebitis of the penis: to study with factor VIII related antigen. *Acta Derm Venereol* 1984;**64**:337–40.

ECHO**Adolescent use of the combined oral contraceptive pill: a retrospective observational study**

N Krishnamoorthy, S Ekins-Daukes, C R Simpson, R M Milne, P J Helms, J S McLay



Please visit the Sexually Transmitted Infections website (www.stijournal.com) for a link to the full text of this article.

Aims: To determine the extent of combined oral contraceptive use by girls aged 10–16 years in Scotland.

Methods: Assessment of combined oral contraceptive prescribing in 35 414 girls for the year 1 November 1999–31 October 2000 from data retrieved from 161 primary care practices taking part in the Scottish Programme for Improving Clinical Effectiveness in Primary Care, and from national aggregated data from family planning clinics.

Results: During the study period the oral contraceptive pill (OCP) was prescribed by a primary care physician to 1531 girls (4.3%) aged 10–16 years. The age specific prevalence rates per 1000 girls registered with their family doctor rose from 0.9/1000 girls aged 12 years or younger, to 6.9, 30, 86.3, and 174.8/1000 for girls aged 13, 14, 15, and 16 years respectively. The overall prevalence of combined oral contraceptive prescribing by primary care physicians was 43.2/1000 girls aged 10–16 years. A further 1765 girls aged 13–16 years obtained a prescription for the OCP from a Scottish family planning clinic, giving an overall prevalence rate for family planning clinic prescribing of 8.0/1000 girls aged 10–16 years. Despite reportedly high levels of sexual activity and teenage pregnancy in this age group, these results confirm that OCP use is relatively low.

Conclusions: The UK has the highest rate of teenage pregnancy in Western Europe, but despite the medical and social concerns about the sexual health of teenagers, the level of oral contraceptive use in this young age group remains low.

▲ *Archives of Disease in Childhood* 2005;**90**:903–905.