

## CHAPTER 8

# ORAL HEALTH COMPLICATIONS IN THE HIV-INFECTED PATIENT – TABLES AND RECOMMENDATIONS

### I. THE ORAL EXAMINATION

#### RECOMMENDATIONS:

Primary health care providers should make an initial dental referral for every patient under their care. Oral health care providers should examine all patients on a semiannual basis for dental prophylaxis and other appropriate preventive care.

The primary health care provider should examine visually and through palpation the patient's lips, labial and buccal mucosa, all surfaces of the tongue and palate, and the floor of the mouth. The gingiva should be examined for signs of erythema, ulceration, or recession.

Patients presenting with oral mucosal, gingival, or dental lesions should be referred promptly to an oral health care provider for appropriate diagnostic evaluation and treatment.

Health care providers should instruct patients in preventive oral health care, including dental visits, brushing, flossing, and the use of fluorides and antimicrobial rinses.

In the later stages of HIV disease, greater numbers of oral lesions and aggressive periodontal breakdown are more likely; therefore, oral health care visits should be scheduled more frequently.

### II. MEDICATIONS AND ORAL HEALTH

Many of the medications received by HIV-infected patients have side effects that may manifest in the oral cavity (see Table 1).

<b>Agent(s)</b>	<b>Potential Side Effect</b>
Antibiotics	May cause or exacerbate candidal growth
Antihistamine, antidepressant, antipsychotic, antihypertensive, and anticholinergic agents	Xerostomia
Clotrimazole troches and nystatin suspension pastilles	Because these agents contain sugar, they may increase the risk of dental caries
Phenytoin	Gingival hyperplasia
Zalcitabine (ddC)	Oral ulcers

### **III. HIV-RELATED ORAL LESIONS**

#### **A. Oral Candidiasis**

##### **1. Diagnosis**

###### **RECOMMENDATION:**

**Diagnosis of oral candidiasis should be made by identification of clinically distinctive lesions, by microscopic examination of cytologic smears or biopsy tissue, or by response to antifungal therapy.**

##### **2. Treatment**

###### **RECOMMENDATIONS:**

**Topical and systemic medications outlined in this section should be used in the treatment of HIV-associated candidiasis (see Tables 2 and 3).**

**Providers should use caution when prescribing systemic antifungal medications to HIV-infected patients because there are significant interactions between systemic antifungal medications and antiretroviral (ARV) agents.**

**Patients should be instructed in proper oral hygiene to prevent caries that may result from the high sugar content in nystatin and clotrimazole. The use of topical fluoride therapy should be considered for patients taking such medication for extended periods of time.**

**When oropharyngeal candidiasis cannot be controlled with topical medication alone, systemic therapy should be initiated. It may be necessary to continue the use of topical medication in addition to systemic medication to control oral candidiasis.**

**A typical antifungal treatment course should be 10 to 14 days, with use of the antifungal agent continued even after clinical signs and symptoms of oral candidiasis have been resolved.**

**Because patients with reduced salivary flow are more susceptible to develop oral candidiasis, salivary flow should be stimulated to help reduce the incidence and severity of oral candidiasis. Chewing sugarless gum or dissolving sugarless lozenges in the mouth can accomplish salivary flow stimulation.**

**TABLE 2**  
**TOPICAL MEDICATIONS FOR ORAL CANDIDIASIS**

<b>Agent</b>	<b>Dispense</b>	<b>Label</b>
Clotrimazole troches (an imidazole)	2- to 4-week supply	Slowly dissolve one 10-mg troche in mouth 5 times/day for treatment.  Slowly dissolve 1 troche in mouth 3 times/day for maintenance therapy.
Nystatin oral suspension (a polyene antifungal agent)*	2- to 4-week supply	Hold 1 teaspoonful (500,000 u) in mouth for 5 minutes, 4 times/day.
Amphotericin B oral suspension (a polyene antifungal agent)†	2- to 4-week supply	Place 1 mL (100 mg) on tongue and swish in mouth for as long as possible before swallowing.
Nystatin vaginal suppositories (a polyene antifungal agent)‡	2- to 4-week supply	Slowly dissolve 1 tablet (100,000 u) in mouth 6 to 8 times/day.

\* Adherence to this regimen is often poor because of the time requirement.

† Used for the treatment of oral candidiasis refractory to nystatin and imidazole preparations.

‡ Although this preparation is not designed for oral use, clinicians have found it useful for treatment of oral candidiasis when the sugar content of other topical anticandidal medications is a concern. The prescription can be written as “nystatin vag. tabs.” A sugarless, flavored lozenge may be dissolved simultaneously in the mouth to mask the taste of nystatin. Adherence with this regimen is often poor because of the time requirement.

**TABLE 3**  
**SYSTEMIC ANTIFUNGAL MEDICATIONS**

<b>Agent</b>	<b>Use</b>
Ketoconazole (an imidazole), fluconazole (a triazole), itraconazole (a triazole)*	Common dosage: ketoconazole 200 mg once daily; fluconazole 100 mg once daily; and itraconazole 200 mg once daily.
Amphotericin B (a polyene antifungal agent)†	Used as an intravenous medication that may be used for candidiasis resistant to other medications. (Note: Amphotericin B is also available as a topical preparation.)

\* Because these medications are easier for patients to use than topical preparations, adherence often improves.

† Azole-resistant fungal infections should be treated with amphotericin B and in consultation with an HIV Specialist.

## **B. Hairy Leukoplakia**

### **1. Diagnosis**

#### **RECOMMENDATIONS:**

**Diagnosis of oral hairy leukoplakia in patients known to be HIV infected should be confirmed by identification of distinct clinical lesions. If the lesions are clinically consistent with hairy leukoplakia and the patient is known to be HIV infected, no further diagnostic procedure is necessary.**

**As in all patients, when an HIV-infected patient presents with a white lesion on the lateral border of the tongue that cannot be diagnosed on the basis of its clinical appearance, biopsy and microscopic examination should be considered.**

### **2. Treatment**

#### **RECOMMENDATION:**

**Hairy leukoplakia generally does not require treatment.**

## **C. Oral Ulcers**

The most commonly reported oral ulcers seen in patients with HIV are herpes simplex ulcers and aphthous ulcers. Oral ulcers may also develop due to other opportunistic diseases, including cytomegalovirus (CMV) infection, histoplasmosis, herpes zoster, and lymphoma. Ulcers associated with zalcitabine (ddC) and foscarnet also have been noted. With accurate diagnosis and appropriate treatment, most oral ulcers resolve in a short time. See **Figure 1** for an algorithm that may assist in the diagnosis and treatment of oral mucosal ulcers.

### **1. Evaluation and General Management**

#### **RECOMMENDATIONS:**

**Diagnosis of oral ulcers should be based on characteristic clinical appearance, the results of cytologic smear, viral culture (isolation), and biopsy and microscopic examination, or response to therapy.**

**If an ulcer does not respond to treatment within 2 weeks, a biopsy and histologic examination should be performed.**

**If the decision is made not to obtain a biopsy of an ulcer that is non-responsive to treatment, the provider should document the rationale for the decision.**

### **2. Herpes Simplex Ulceration**

#### **a. Diagnosis**

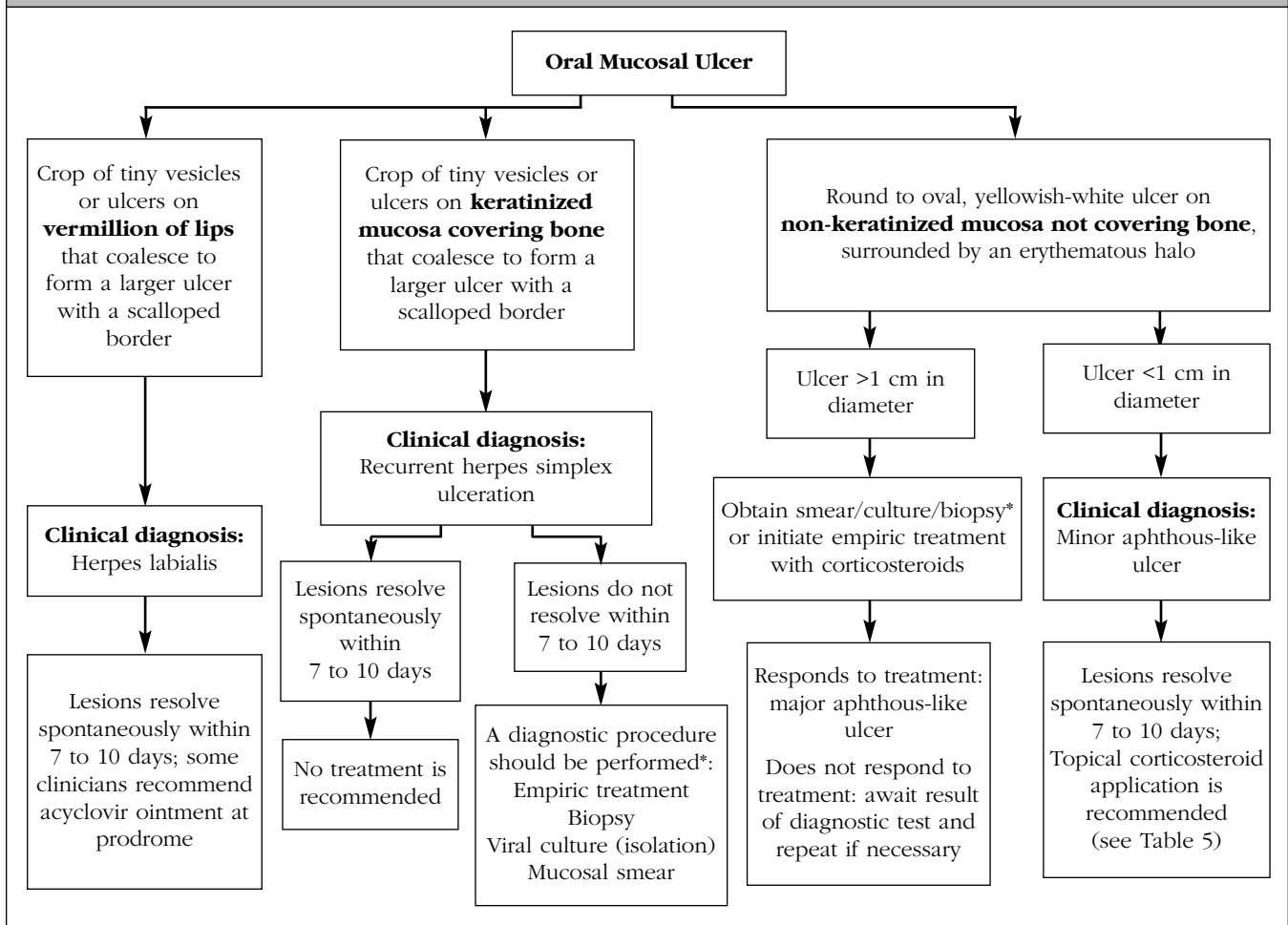
##### **RECOMMENDATIONS:**

**Diagnosis of typical recurrent herpes simplex ulceration should be made by recognizing the typical clinical appearance on the labial vermilion border or intraorally on keratinized mucosa attached to bone.**

**Viral culture, mucosal smear, biopsy, and response to acyclovir are recommended options to accurately diagnose HSV-associated ulcers.**

**As atypical herpetic ulcers may be the first sign of immunosuppression, patients with these ulcers should be referred for HIV counseling and testing.**

**FIGURE 1**  
**DIAGNOSIS AND TREATMENT OF ORAL MUCOSAL ULCERS**



**\* Possible diagnosis and treatment:**

- Atypical herpes simplex ulceration: See Table 4
- Major aphthous-like ulcer: See Table 5
- Cytomegalovirus ulceration: See Page 8-7
- Ulceration due to other infectious agents: See Page 8-8
- Lymphoma: Refer to an HIV Specialist for treatment recommendations

**b. Treatment**

**RECOMMENDATION:**

**While awaiting confirmation of the diagnosis, providers should consider initiation of systemic acyclovir treatment if HSV ulceration is suspected (see Table 4). Response to this medication may be helpful in confirming the diagnosis.**

**3. Aphthous Ulcers**

**a. Diagnosis**

**RECOMMENDATION:**

**Diagnosis of aphthous ulcers should be based on the characteristic clinical appearance of painful, round-to-oval, yellow-white ulcers surrounded by a halo of erythema. For all ulcers not exhibiting these characteristic clinical features or when empiric therapy has failed, viral culture (isolation), mucosal smear, or biopsy may be necessary to rule out ulcers caused by opportunistic infections.**

<b>TABLE 4 TREATMENT REGIMEN FOR ATYPICAL HSV</b>		
<b>Agent</b>	<b>Dispense</b>	<b>Label</b>
Acyclovir 200-mg capsules*†	2- to 4-week supply	Take 1 to 2 capsules 5 times/day for 10 days. Dosage will vary depending on clinical severity and the immunologic status of the patient.

\* Valacyclovir is the prodrug of acyclovir and is commonly used.

† Acyclovir-resistant herpes simplex ulcerations should be considered when ulcers with a confirmed diagnosis of HSV infection do not respond to acyclovir. Treatment with foscarnet is recommended for such lesions.

**b. Treatment**

**RECOMMENDATION:**

**The management of aphthous ulcers should include the use of topical corticosteroids; however, caution should be taken because steroid use may result in candidal overgrowth.**

Some clinicians have found systemic corticosteroids useful for the treatment of ulcers not easily accessible for application of topical medications or for patients not able to adhere to topical regimens; however, systemic corticosteroids are usually not necessary in the treatment of localized oral aphthous ulcerations. The agents listed in **Table 5** are used to treat aphthous ulcers.

TABLE 5 TREATMENT OF APHTHOUS ULCERS		
Agent	Dispense	Label
Fluocinonide ointment 0.05% and hydrocortisone acetate oral paste	2- to 4-week supply; mix equal parts hydrocortisone acetate oral paste with fluocinonide ointment to form a compound	Apply compound to ulcer(s) 5 to 6 times/day
Fluocinonide gel 0.05%	2- to 4-week supply	Apply to ulcer(s) 5 to 6 times/day
Clobetasol propionate ointment 0.05% and hydrocortisone acetate oral paste <sup>3</sup>	2- to 4-week supply; mix equal parts hydrocortisone acetate oral paste with clobetasol propionate ointment to form a compound	Apply compound to ulcer(s) 2 times/day
Dexamethasone elixir 0.5 mg/5 mL*	2- to 4-week supply	Use as an oral rinse 4 to 6 times/day (swish and expectorate) or apply directly to ulceration by saturating a gauze sponge and applying topically to lesion 5 to 10 minutes 4 times/day.

\* Used for multiple ulcers or ulcers not easily accessible for topical application.

#### 4. Cytomegalovirus Oral Ulceration

##### a. Diagnosis

**RECOMMENDATION:**

**Diagnosis of an oral ulcer due to CMV should be established by biopsy and histologic examination.**

##### b. Treatment

**RECOMMENDATION:**

**Foscavir, ganciclovir, or cidofovir should be used to treat CMV.**

#### 5. Other Ulcers

##### a. Diagnosis

**RECOMMENDATION:**

**Diagnosis of oral ulceration due to other infectious agents such as *Histoplasma capsulatum* (histoplasmosis), *Cryptococcus neoformans* (cryptococcosis), and *Aspergillus* organisms should be made by biopsy and histologic examination.**

##### b. Treatment

**RECOMMENDATION:**

**Treatment should be based on identification of the causative organism.**

## **D. Oral Kaposi's Sarcoma**

### **1. Diagnosis**

#### **RECOMMENDATION:**

The diagnosis of Kaposi's sarcoma should be confirmed by either biopsy or identification of distinct clinical appearance.

## **IV. HIV-RELATED PERIODONTAL DISEASE**

### **A. Linear Gingival Erythema**

#### **1. Diagnosis**

#### **RECOMMENDATION:**

The diagnosis of LGE is made on the basis of distinctive clinical characteristics.

#### **2. Treatment**

#### **RECOMMENDATION:**

Patients with LGE should be referred to an oral health care provider who has experience in the management of patients with HIV disease. For additional information, refer to the New York State Department of Health AIDS Institute's oral health guidelines.<sup>5</sup>

### **B. Necrotizing Ulcerative Periodontitis**

#### **1. Diagnosis**

#### **RECOMMENDATION:**

The diagnosis of NUP should be made on the basis of distinctive clinical characteristics.

## **V. SALIVARY GLAND DISEASE ASSOCIATED WITH HIV INFECTION**

#### **RECOMMENDATION:**

For patients with xerostomia, additional measures should be employed to prevent dental caries and periodontal disease. Such measures include topical fluoride therapy, chlorhexidine oral rinse, decreased sugar consumption, and meticulous oral hygiene. The use of saliva substitutes should also be considered.

## **VI. HUMAN PAPILLOMAVIRUS INFECTION**

### **A. Diagnosis**

#### **RECOMMENDATION:**

Diagnosis of HPV lesions should be made by routine biopsy and histologic examination.

## REFERENCES

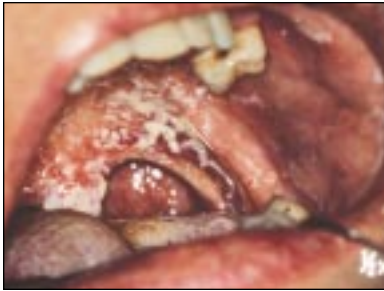1. Kaplan JE, Hanson DL, Navin TR, Jones JK. Risk factors for primary *Pneumocystis carinii* pneumonia in human immunodeficiency virus-infected adolescents and adults in the United States: Reassessment of indications for chemoprophylaxis. *J Infect Dis* 1998;178:1126-1132.
2. Centers for Disease Control and Prevention. 1993 Revised classification system for HIV infection and expanded surveillance case definition for AIDS among adolescents and adults. *MMWR Morb Mortal Wkly Rep* 1992;41(RR-17):1-19.
3. Lozada-Nur F, Miranda C, Maliiksi R. Double-blind clinical trial of 0.05% clobetasol propionate in orabase and 0.05% fluocinonide ointment in orabase in the treatment of patients with oral vesiculoerosive disease. *Oral Surg Oral Med Oral Pathol* 1994;77:598-604.
4. Jacobson JM, Greenspan JS, Spritzler J, Ketter N, Fahey JL, Jackson JB, et al. Thalidomide for the treatment of oral aphthous ulcers in patients with human immunodeficiency virus infection. *N Engl J Med* 1997;336:1487-1493.
5. Dental Standards of Care Committee. *Oral Health Care for People With HIV Infection*. New York, NY: New York State Department of Health AIDS Institute; 2001.
6. Navazesh M, Mulligan R, Komaroff E, Redford M, Greenspan D, Phelan J. The prevalence of xerostomia and salivary gland hypofunction in a cohort of HIV-positive and at-risk women. *J Dent Res* 2000;79:1502-1507.
7. Mulligan R, Navazesh M, Komaroff E, Greenspan D, Redford M, Alves M, et al. Salivary gland disease in human immunodeficiency virus-positive women from the WIHS study. *Oral Surg Oral Med Oral Pathol Oral Radiol Endod* 2000;89:702-709.

## FURTHER READING

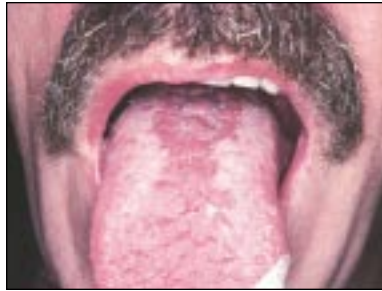- American Dental Association and American Academy of Oral Medicine. Dental management of the HIV-infected patient. *J Am Dent Assoc* 1995;(Suppl):34-39.
- Glick M. *Dental Management of Patients with HIV*. Chicago, IL: Quintessence Publishing Co, Inc; 1994:153-182.

# APPENDIX 8-A

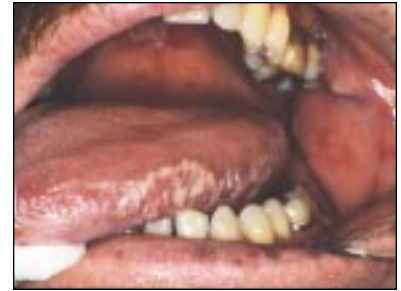## ORAL LESIONS ASSOCIATED WITH HIV INFECTION



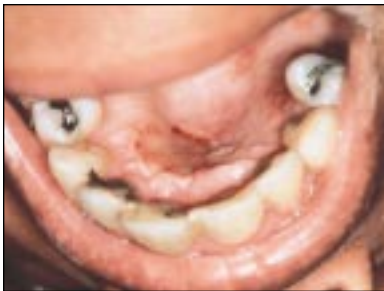**Pseudomembraneous candidiasis**



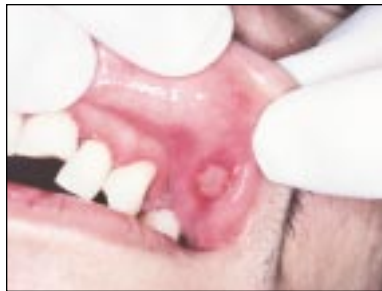**Erythematous candidiasis**



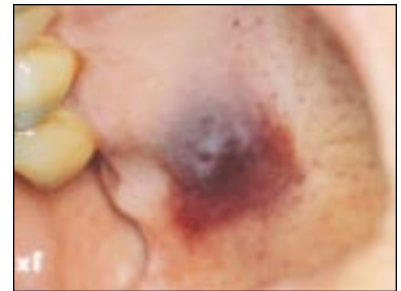
**Hairy leukoplakia**



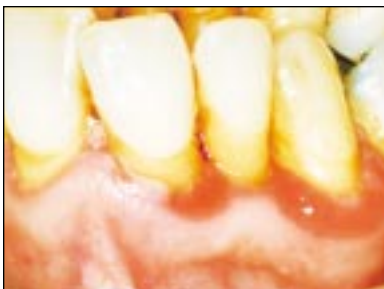**Herpes simplex ulceration**



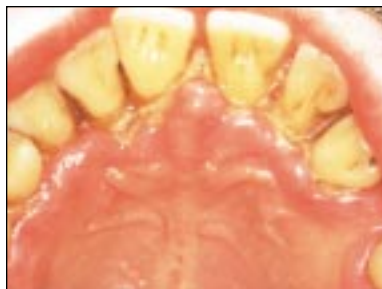**Aphthous ulceration**



**Kaposi's sarcoma**



**Linear gingival erythema**



**Necrotizing ulcerative  
periodontitis**