

CHAPTER 8

ORAL HEALTH COMPLICATIONS IN THE HIV-INFECTED PATIENT

Oral health care is a critical component of comprehensive HIV medical management. Development of oral pathology is frequently associated with an underlying progression of HIV-disease status. A thorough soft-tissue examination may reveal pathology associated with dysphagia or odynophagia. Dental problems can result in or exacerbate nutritional problems. In addition, psychosocial and quality-of-life issues frequently are associated with the condition of the oral cavity and the dentition.

I. THE ORAL EXAMINATION

RECOMMENDATIONS:

Primary health care providers should make an initial dental referral for every patient under their care. Oral health care providers should examine all patients on a semiannual basis for dental prophylaxis and other appropriate preventive care.

The primary health care provider should examine visually and through palpation the patient's lips, labial and buccal mucosa, all surfaces of the tongue and palate, and the floor of the mouth. The gingiva should be examined for signs of erythema, ulceration, or recession.

Patients presenting with oral mucosal, gingival, or dental lesions should be referred promptly to an oral health care provider for appropriate diagnostic evaluation and treatment.

Health care providers should instruct patients in preventive oral health care, including dental visits, brushing, flossing, and the use of fluorides and antimicrobial rinses.

In the later stages of HIV disease, greater numbers of oral lesions and aggressive periodontal breakdown are more likely; therefore, oral health care visits should be scheduled more frequently.

II. MEDICATIONS AND ORAL HEALTH

Many of the medications received by HIV-infected patients have side effects that may manifest in the oral cavity (see Table 1).

Agent(s)	Potential Side Effect
Antibiotics	May cause or exacerbate candidal growth
Antihistamine, antidepressant, antipsychotic, antihypertensive, and anticholinergic agents	Xerostomia
Clotrimazole troches and nystatin suspension pastilles	Because these agents contain sugar, they may increase the risk of dental caries
Phenytoin	Gingival hyperplasia
Zalcitabine (ddC)	Oral ulcers

III. HIV-RELATED ORAL LESIONS

A. Oral Candidiasis

Oral candidiasis is caused by one of the *Candida* species, usually *Candida albicans*, a normal inhabitant of the oral cavity in many healthy individuals. In individuals infected with HIV, the development of oral candidiasis may be an indication of immune deterioration and has prognostic significance for the development of AIDS. Oral candidiasis may precede other signs of immune deficiency and is one of the clinical indicators for initiating and continuing prophylaxis for *Pneumocystis carinii* pneumonia (PCP).¹ See Appendix 8-A for photographic examples of candidiasis.

1. Diagnosis

RECOMMENDATION:

Diagnosis of oral candidiasis should be made by identification of clinically distinctive lesions, by microscopic examination of cytologic smears or biopsy tissue, or by response to antifungal therapy.

2. Treatment

RECOMMENDATIONS:

Topical and systemic medications outlined in this section should be used in the treatment of HIV-associated candidiasis (see Tables 2 and 3).

Providers should use caution when prescribing systemic antifungal medications to HIV-infected patients because there are significant interactions between systemic antifungal medications and antiretroviral (ARV) agents.

Patients should be instructed in proper oral hygiene to prevent caries that may result from the high sugar content in nystatin and clotrimazole. The use of topical fluoride therapy should be considered for patients taking such medication for extended periods of time.

When oropharyngeal candidiasis cannot be controlled with topical medication alone, systemic therapy should be initiated. It may be necessary to continue the use of topical medication in addition to systemic medication to control oral candidiasis.

A typical antifungal treatment course should be 10 to 14 days, with use of the antifungal agent continued even after clinical signs and symptoms of oral candidiasis have been resolved.

Because patients with reduced salivary flow are more susceptible to develop oral candidiasis, salivary flow should be stimulated to help reduce the incidence and severity of oral candidiasis. Chewing sugarless gum or dissolving sugarless lozenges in the mouth can accomplish salivary flow stimulation.

TABLE 2
TOPICAL MEDICATIONS FOR ORAL CANDIDIASIS

Agent	Dispense	Label
Clotrimazole troches (an imidazole)	2- to 4-week supply	Slowly dissolve one 10-mg troche in mouth 5 times/day for treatment. Slowly dissolve 1 troche in mouth 3 times/day for maintenance therapy.
Nystatin oral suspension (a polyene antifungal agent)*	2- to 4-week supply	Hold 1 teaspoonful (500,000 u) in mouth for 5 minutes, 4 times/day.
Amphotericin B oral suspension (a polyene antifungal agent)†	2- to 4-week supply	Place 1 mL (100 mg) on tongue and swish in mouth for as long as possible before swallowing.
Nystatin vaginal suppositories (a polyene antifungal agent)‡	2- to 4-week supply	Slowly dissolve 1 tablet (100,000 u) in mouth 6 to 8 times/day.

* Adherence to this regimen is often poor because of the time requirement.

† Used for the treatment of oral candidiasis refractory to nystatin and imidazole preparations.

‡ Although this preparation is not designed for oral use, clinicians have found it useful for treatment of oral candidiasis when the sugar content of other topical anticandidal medications is a concern. The prescription can be written as “nystatin vag. tabs.” A sugarless, flavored lozenge may be dissolved simultaneously in the mouth to mask the taste of nystatin. Adherence with this regimen is often poor because of the time requirement.

TABLE 3
SYSTEMIC ANTIFUNGAL MEDICATIONS

Agent	Use
Ketoconazole (an imidazole), fluconazole (a triazole), itraconazole (a triazole)*	Common dosage: ketoconazole 200 mg once daily; fluconazole 100 mg once daily; and itraconazole 200 mg once daily.
Amphotericin B (a polyene antifungal agent)†	Used as an intravenous medication that may be used for candidiasis resistant to other medications. (Note: Amphotericin B is also available as a topical preparation.)

* Because these medications are easier for patients to use than topical preparations, adherence often improves.

† Azole-resistant fungal infections should be treated with amphotericin B and in consultation with an HIV Specialist.

B. Hairy Leukoplakia

Hairy leukoplakia most commonly presents as a white, ragged, corrugated, or irregular lesion involving the lateral and dorsolateral tongue. Lesions may be unilateral or bilateral. Hairy leukoplakia is caused by infection of the lesional epithelial cells with Epstein-Barr virus (EBV) and is associated with immune deterioration. Hairy leukoplakia involving other mucosal surfaces also has been reported. See Appendix 8-A for a photographic example of hairy leukoplakia.

1. Diagnosis

RECOMMENDATIONS:

Diagnosis of oral hairy leukoplakia in patients known to be HIV infected should be confirmed by identification of distinct clinical lesions. If the lesions are clinically consistent with hairy leukoplakia and the patient is known to be HIV infected, no further diagnostic procedure is necessary.

As in all patients, when an HIV-infected patient presents with a white lesion on the lateral border of the tongue that cannot be diagnosed on the basis of its clinical appearance, biopsy and microscopic examination should be considered.

Histologically, hairy leukoplakia exhibits hyperparakeratosis, often with hair-like projections, epithelial hyperplasia, vacuolated epithelial cells (koilocyte-like), and little or no inflammatory infiltrate in the underlying connective tissue. Changes have been reported in the nuclei of epithelial cells infected with EBV, which can be seen by light microscopic examination. Hybridization techniques also have been used to identify EBV in biopsy specimens. If a patient's HIV status is unknown, a biopsy and identification of EBV in the epithelial cells of the lesion may be considered before recommending HIV testing.

2. Treatment

RECOMMENDATION:

Hairy leukoplakia generally does not require treatment.

For some patients, hairy leukoplakia lesions may be cosmetically objectionable. Hairy leukoplakia has been treated successfully with systemic acyclovir, although it usually recurs when treatment is discontinued. Hairy leukoplakia also has been reported to resolve with zidovudine, podophyllin, and interferon. Regardless of treatment, the lesions may wax and wane.

C. Oral Ulcers

The most commonly reported oral ulcers seen in patients with HIV are herpes simplex ulcers and aphthous ulcers. Oral ulcers may also develop due to other opportunistic diseases, including cytomegalovirus (CMV) infection, histoplasmosis, herpes zoster, and lymphoma. Ulcers associated with zalcitabine (ddC) and foscarnet also have been noted. With accurate diagnosis and appropriate treatment, most oral ulcers resolve in a short time. See Figure 1 for an algorithm that may assist in the diagnosis and treatment of oral mucosal ulcers.

1. Evaluation and General Management

RECOMMENDATIONS:

Diagnosis of oral ulcers should be based on characteristic clinical appearance, the results of cytologic smear, viral culture (isolation), and biopsy and microscopic examination, or response to therapy.

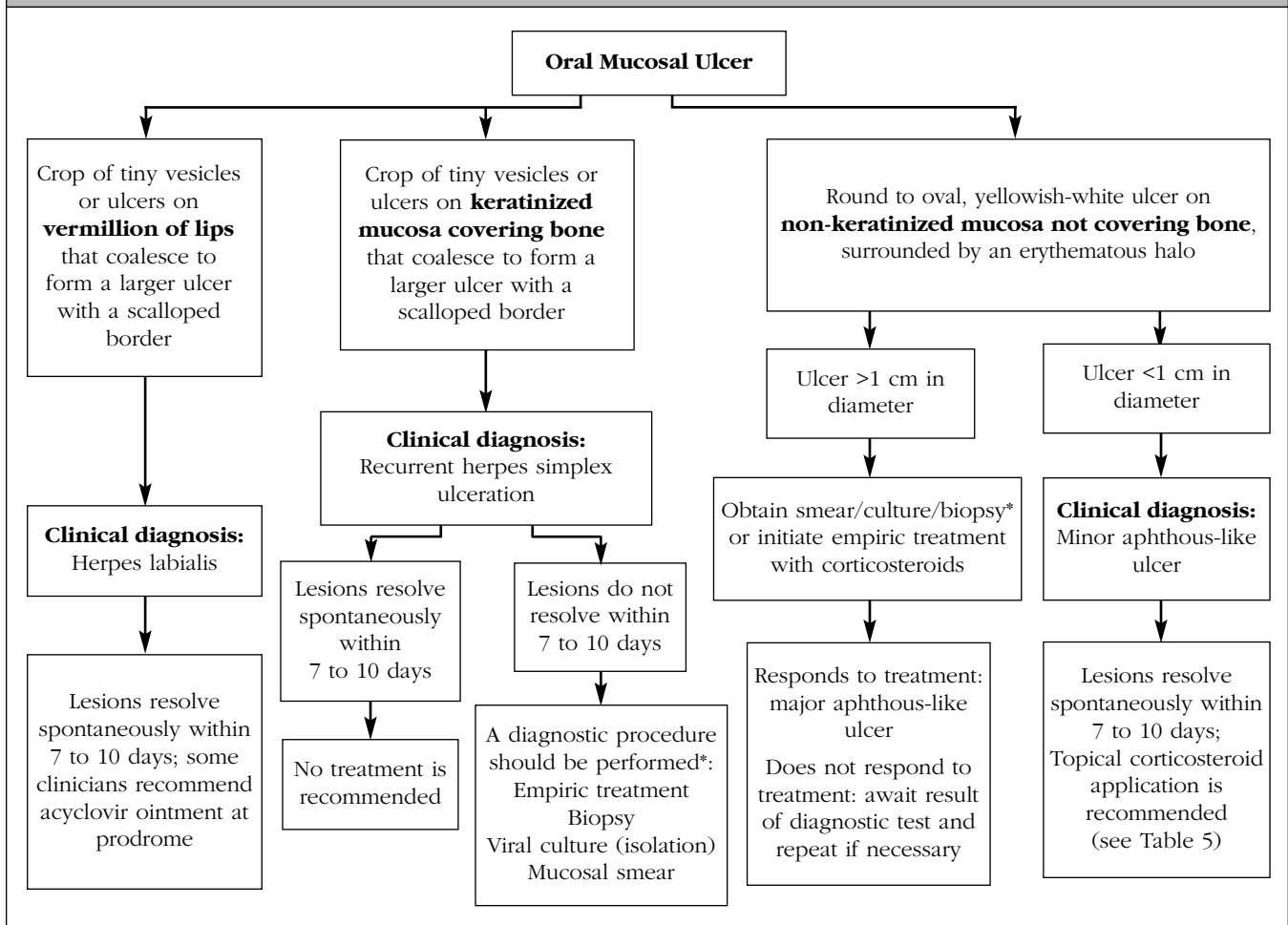
If an ulcer does not respond to treatment within 2 weeks, a biopsy and histologic examination should be performed.

If the decision is made not to obtain a biopsy of an ulcer that is non-responsive to treatment, the provider should document the rationale for the decision.

2. Herpes Simplex Ulceration

In immunocompetent patients, oral ulcers caused by the herpes simplex virus (HSV) occur in primary infection form (primary herpetic gingivostomatitis) and recurrent forms (herpes labialis and recurrent intraoral herpes simplex ulceration). The primary infection most commonly occurs in children but also may occur in adults. Recurrent ulcers occur due to reactivation of latent infection.

FIGURE 1
DIAGNOSIS AND TREATMENT OF ORAL MUCOSAL ULCERS



*** Possible diagnosis and treatment:**

- Atypical herpes simplex ulceration: See Table 4
- Major aphthous-like ulcer: See Table 5
- Cytomegalovirus ulceration: See Page 8-7
- Ulceration due to other infectious agents: See Page 8-8
- Lymphoma: Refer to an HIV Specialist for treatment recommendations

Herpes labialis appears as a crop of vesicles that coalesce and form an irregular ulcer on the vermillion of the lips or perioral skin. Intraoral recurrent herpes simplex infection presents as a localized crop of vesicles that characteristically form only on keratinized mucosa. In immunocompetent individuals, these ulcers follow a predictable course and usually resolve spontaneously in 7 to 10 days.

In patients with HIV infection who have marked immune deficiency, ulcers caused by herpes simplex infection tend to be persistent, superficial (infecting the epithelium and not connective tissue), and painful. Persistent herpetic lesions in HIV-infected patients that do not resolve after 4 weeks fulfill the Centers for Disease Control and Prevention (CDC) criteria for a diagnosis of AIDS.² These ulcers do not have a characteristic clinical appearance and may appear to be similar to ulcers caused by other agents or circumstances. These ulcers differ from herpes simplex ulceration in immunocompetent individuals in that they can occur anywhere in the oral cavity, are larger, present for longer periods of time, and are non-responsive to routine therapy. Atypical herpetic ulcers may be the first sign of immunosuppression and may signal a need for HIV counseling and testing. See Appendix 8-A for a photographic example of herpes simplex infection.

a. Diagnosis

RECOMMENDATIONS:

Diagnosis of typical recurrent herpes simplex ulceration should be made by recognizing the typical clinical appearance on the labial vermilion border or intraorally on keratinized mucosa attached to bone.

Viral culture, mucosal smear, biopsy, and response to acyclovir are recommended options to accurately diagnose HSV-associated ulcers.

As atypical herpetic ulcers may be the first sign of immunosuppression, patients with these ulcers should be referred for HIV counseling and testing.

b. Treatment

RECOMMENDATION:

While awaiting confirmation of the diagnosis, providers should consider initiation of systemic acyclovir treatment if HSV ulceration is suspected (see Table 4). Response to this medication may be helpful in confirming the diagnosis.

TABLE 4 TREATMENT REGIMEN FOR ATYPICAL HSV		
Agent	Dispense	Label
Acyclovir 200-mg capsules*†	2- to 4-week supply	Take 1 to 2 capsules 5 times/day for 10 days. Dosage will vary depending on clinical severity and the immunologic status of the patient.

* Valacyclovir is the prodrug of acyclovir and is commonly used.

† Acyclovir-resistant herpes simplex ulcerations should be considered when ulcers with a confirmed diagnosis of HSV infection do not respond to acyclovir. Treatment with foscarnet is recommended for such lesions.

3. Aphthous Ulcers

a. Diagnosis

RECOMMENDATION:

Diagnosis of aphthous ulcers should be based on the characteristic clinical appearance of painful, round-to-oval, yellow-white ulcers surrounded by a halo of erythema. For all ulcers not exhibiting these characteristic clinical features or when empiric therapy has failed, viral culture (isolation), mucosal smear, or biopsy may be necessary to rule out ulcers caused by opportunistic infections.

Increased frequency and severity of episodes of typical minor aphthous ulcers have been reported in patients with HIV. Major aphthous-like ulcers, also called ulcerative stomatitis, present as persistent, deep, crater-like lesions that extend through the epithelium into the connective tissues.

Although much less common, the herpetiform type of aphthous stomatitis also has been reported in patients with HIV. As in non-HIV-infected patients, these ulcers generally occur on non-keratinized oral mucosa but can present in any location. See Appendix 8-A for a photographic example of aphthous ulceration.

b. Treatment

RECOMMENDATION:

The management of aphthous ulcers should include the use of topical corticosteroids; however, caution should be taken because steroid use may result in candidal overgrowth.

Some clinicians have found systemic corticosteroids useful for the treatment of ulcers not easily accessible for application of topical medications or for patients not able to adhere to topical regimens; however, systemic corticosteroids are usually not necessary in the treatment of localized oral aphthous ulcerations. The agents listed in Table 5 are used to treat aphthous ulcers.

Thalidomide has been shown to be effective for the treatment of non-resolving aphthous ulcers in HIV-positive patients⁴; however, there are serious documented teratogenic effects associated with thalidomide in pregnant women. Because of these severe side effects, thalidomide should only be used when all other options have been exhausted. In adolescent and adult women capable of bearing children, thalidomide should only be used when the woman is known not to be pregnant and is using effective methods of birth control.

TABLE 5 TREATMENT OF APHTHOUS ULCERS		
Agent	Dispense	Label
Fluocinonide ointment 0.05% and hydrocortisone acetate oral paste	2- to 4-week supply; mix equal parts hydrocortisone acetate oral paste with fluocinonide ointment to form a compound	Apply compound to ulcer(s) 5 to 6 times/day
Fluocinonide gel 0.05%	2- to 4-week supply	Apply to ulcer(s) 5 to 6 times/day
Clobetasol propionate ointment 0.05% and hydrocortisone acetate oral paste ³	2- to 4-week supply; mix equal parts hydrocortisone acetate oral paste with clobetasol propionate ointment to form a compound	Apply compound to ulcer(s) 2 times/day
Dexamethasone elixir 0.5 mg/5 mL*	2- to 4-week supply	Use as an oral rinse 4 to 6 times/day (swish and expectorate) or apply directly to ulceration by saturating a gauze sponge and applying topically to lesion 5 to 10 minutes 4 times/day.

* Used for multiple ulcers or ulcers not easily accessible for topical application.

4. Cytomegalovirus Oral Ulceration

CMV is a herpes-type virus. Serologic evidence of a history of CMV infection is present in up to 80% of HIV-infected adults studied. Cases of CMV-related oral ulceration have been reported in patients with HIV infection. The presence of CMV suggests immunosuppression.

a. Diagnosis

RECOMMENDATION:

Diagnosis of an oral ulcer due to CMV should be established by biopsy and histologic examination.

Oral ulcers due to CMV may occur anywhere in the oral cavity; characteristic clinical features have not been identified. Cells exhibiting characteristic intranuclear and intracytoplasmic inclusions are seen on microscopic examination.

b. Treatment

RECOMMENDATION:

Foscavir, ganciclovir, or cidofovir should be used to treat CMV.

5. Other Ulcers

a. Diagnosis

RECOMMENDATION:

Diagnosis of oral ulceration due to other infectious agents such as *Histoplasma capsulatum* (histoplasmosis), *Cryptococcus neoformans* (cryptococcosis), and *Aspergillus* organisms should be made by biopsy and histologic examination.

Oral lesions due to these organisms are signs of disseminated disease.

b. Treatment

RECOMMENDATION:

Treatment should be based on identification of the causative organism.

D. Oral Kaposi's Sarcoma

Kaposi's sarcoma has been the most common malignant tumor associated with HIV infection. Since the introduction of ARV agents, the occurrence seems to be rare. Herpes virus (HHV-8) has been implicated in the etiology of Kaposi's sarcoma. Kaposi's sarcoma oral lesions may interfere with function, be cosmetically objectionable, and proliferate uncontrollably. The palate is by far the most commonly affected oral site, followed by the maxillary gingiva. The lesions are often multifocal and usually present as flat purple plaques or raised nodules. See Appendix 8-A for a photographic example of Kaposi's sarcoma.

1. Diagnosis

RECOMMENDATION:

The diagnosis of Kaposi's sarcoma should be confirmed by either biopsy or identification of distinct clinical appearance.

Clinical appearance may be sufficient to diagnose Kaposi's sarcoma, especially if the patient has a previous biopsy-confirmed diagnosis of Kaposi's sarcoma at another site.

2. Treatment

There is no consistently effective management for Kaposi's sarcoma. Systemic chemotherapy is used, and intralesional injections of vincristine, vinblastine, or interferon- α have been used with some success. Intralesional injections with sodium tetradecyl sulfate, a sclerosing solution, also have been effective. Radiation therapy has also been successful for treatment of oral Kaposi's sarcoma lesions. Surgical excision of a portion of the lesion may be helpful to allow restoration of teeth or to prevent interference with function. Patients who are successfully treated with ARV medications usually experience remission of Kaposi's sarcoma lesions.

IV. HIV-RELATED PERIODONTAL DISEASE

Two types of gingival/periodontal disease associated with HIV infection have been widely reported in the literature. In the past, these have been called HIV-associated gingivitis (HIV-G) and HIV-associated periodontitis (HIV-P). There is now evidence that these diseases also occur in HIV-negative immunocompromised individuals and are not specific to HIV infection, thus making the original terms inappropriate. Therefore, HIV-associated gingivitis has been renamed linear gingival erythema (LGE) and HIV-associated periodontitis has been renamed necrotizing ulcerative periodontitis (NUP).

The prevalence of these two diseases remains unclear, with estimates of occurrence among HIV-infected individuals ranging from 5% to 50%. It is not yet clear where in the spectrum of HIV disease these conditions occur or which patients are at greatest risk of developing them. There is some evidence that NUP is associated with a low CD4 count (<200 cells/mm³).

A. Linear Gingival Erythema

1. Diagnosis

RECOMMENDATION:

The diagnosis of LGE is made on the basis of distinctive clinical characteristics.

LGE is limited to the soft tissue of the periodontium and characteristically appears as an erythematous linear band that extends approximately 2 mm to 3 mm from the free gingival margin. There also may be punctate erythema, which extends onto the alveolar mucosa. At times, these areas coalesce, creating broadly diffuse erythematous zones from the gingival margin into the vestibule. Unlike conventional gingivitis, LGE is not significantly associated with plaque. In most cases of LGE, gentle probing produces bleeding. See Appendix 8-A for a photographic example of LGE.

2. Treatment

RECOMMENDATION:

Patients with LGE should be referred to an oral health care provider who has experience in the management of patients with HIV disease. For additional information, refer to the New York State Department of Health AIDS Institute's oral health guidelines.⁵

B. Necrotizing Ulcerative Periodontitis

1. Diagnosis

RECOMMENDATION:

The diagnosis of NUP should be made on the basis of distinctive clinical characteristics.

NUP affects the osseous structures of the periodontium. Clinical features include pain, interproximal gingival necrosis, and cratered soft tissues. Patients frequently complain of spontaneous bleeding and deep-seated pain in the jaws. Destruction of the periodontal attachment and bone can be extremely rapid and extensive and may result in as much as 90% bone loss around isolated teeth in as few as 12 weeks. If left untreated, NUP may extend into the contiguous tissues and expose the alveolar or palatal bone. When this occurs, the condition has been called necrotizing stomatitis. See Appendix 8-A for a photographic example of NUP.

2. Treatment

Patients with NUP should be referred to an oral health care provider who has experience in the management of patients with HIV disease. For additional information, refer to the New York State Department of Health AIDS Institute's oral health guidelines.⁵

C. Necrotizing Ulcerative Gingivitis

Necrotizing ulcerative gingivitis (NUG) has been associated with HIV infections. NUG and NUP may represent different stages of the same pathologic process, with NUP being a later stage of NUG.

V. SALIVARY GLAND DISEASE ASSOCIATED WITH HIV INFECTION

RECOMMENDATION:

For patients with xerostomia, additional measures should be employed to prevent dental caries and periodontal disease. Such measures include topical fluoride therapy, chlorhexidine oral rinse, decreased sugar consumption, and meticulous oral hygiene. The use of saliva substitutes should also be considered.

Xerostomia (dry mouth) has been associated with HIV infection.⁶ Although its prevalence and cause are not clear, xerostomia may be due to medications or to HIV-related salivary gland disease. The presence of xerostomia increases the risk of the development of dental caries and periodontal disease. Bilateral parotid gland enlargement can occur in both children and adults who are HIV positive, but the clinical significance is unclear.⁷ In some patients, a complex similar to Sjögren's syndrome has been described, and the histologic appearance of cystic benign lymphoepithelial lesions has been reported.

VI. HUMAN PAPILLOMAVIRUS INFECTION

Lesions caused by human papillomavirus (HPV) present as papillary lesions that may be of normal mucosal color, slightly erythematous, or hyperkeratotic. In patients with HIV, these lesions may be florid with numerous papillomas, or they may present with fewer and larger papillary projections.

A. Diagnosis

RECOMMENDATION:

Diagnosis of HPV lesions should be made by routine biopsy and histologic examination.

Immunofluorescence or immunoperoxidase staining for papillomavirus can be done to determine the strain of HPV infecting the tissue.

B. Treatment

Surgical excision of the lesions is the most widely used treatment for oral papillomas. Recurrence is common for lesions caused by HPV. Some clinicians believe that cauterization of the base of the lesion following excision helps minimize re-infection from the surgical site. Intralesional interferon and topical application of podophyllin are other approaches to treatment of these lesions.

REFERENCES

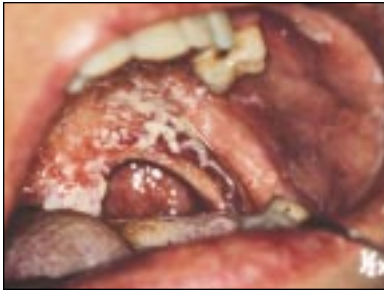1. Kaplan JE, Hanson DL, Navin TR, Jones JK. Risk factors for primary *Pneumocystis carinii* pneumonia in human immunodeficiency virus-infected adolescents and adults in the United States: Reassessment of indications for chemoprophylaxis. *J Infect Dis* 1998;178:1126-1132.
2. Centers for Disease Control and Prevention. 1993 Revised classification system for HIV infection and expanded surveillance case definition for AIDS among adolescents and adults. *MMWR Morb Mortal Wkly Rep* 1992;41(RR-17):1-19.
3. Lozada-Nur F, Miranda C, Maliiksi R. Double-blind clinical trial of 0.05% clobetasol propionate in orabase and 0.05% fluocinonide ointment in orabase in the treatment of patients with oral vesiculoerosive disease. *Oral Surg Oral Med Oral Pathol* 1994;77:598-604.
4. Jacobson JM, Greenspan JS, Spritzler J, Ketter N, Fahey JL, Jackson JB, et al. Thalidomide for the treatment of oral aphthous ulcers in patients with human immunodeficiency virus infection. *N Engl J Med* 1997;336:1487-1493.
5. Dental Standards of Care Committee. *Oral Health Care for People With HIV Infection*. New York, NY: New York State Department of Health AIDS Institute; 2001.
6. Navazesh M, Mulligan R, Komaroff E, Redford M, Greenspan D, Phelan J. The prevalence of xerostomia and salivary gland hypofunction in a cohort of HIV-positive and at-risk women. *J Dent Res* 2000;79:1502-1507.
7. Mulligan R, Navazesh M, Komaroff E, Greenspan D, Redford M, Alves M, et al. Salivary gland disease in human immunodeficiency virus-positive women from the WIHS study. *Oral Surg Oral Med Oral Pathol Oral Radiol Endod* 2000;89:702-709.

FURTHER READING

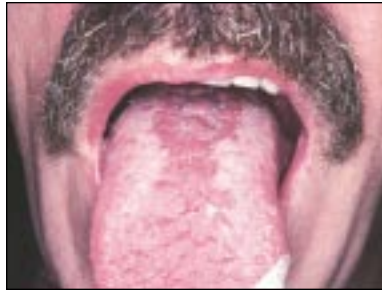- American Dental Association and American Academy of Oral Medicine. Dental management of the HIV-infected patient. *J Am Dent Assoc* 1995;(Suppl):34-39.
- Glick M. *Dental Management of Patients with HIV*. Chicago, IL: Quintessence Publishing Co, Inc; 1994:153-182.

APPENDIX 8-A

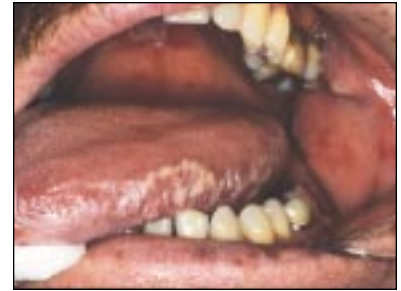ORAL LESIONS ASSOCIATED WITH HIV INFECTION



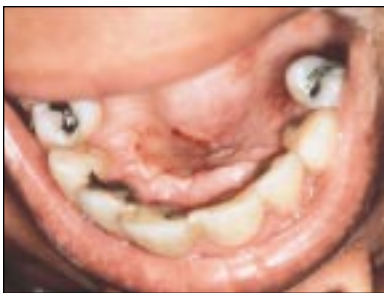Pseudomembranous candidiasis



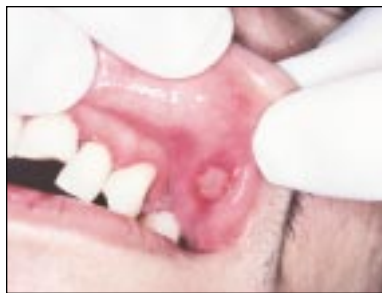Erythematous candidiasis



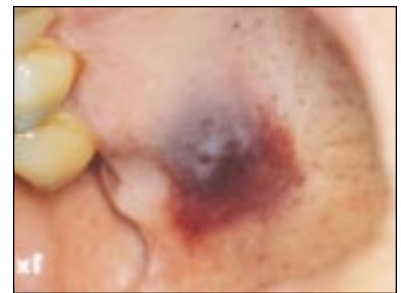
Hairy leukoplakia



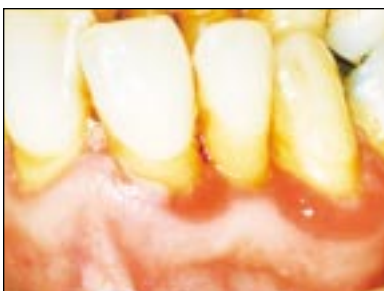Herpes simplex ulceration



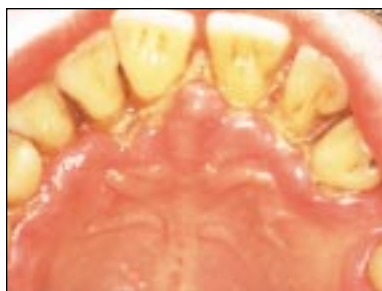Aphthous ulceration



Kaposi's sarcoma



Linear gingival erythema



**Necrotizing ulcerative
periodontitis**

