



Published in final edited form as:

Urol Clin North Am. 2005 November ; 32(4): 379–v.

Physiology of Penile Erection and Pathophysiology of Erectile Dysfunction

Robert C. Dean, MD^a and Tom F. Lue, MD^b

^a *Clinical Fellow, Department of Urology, University of California, San Francisco Medical Center, San Francisco, California; and*

^b *Professor and Vice-Chair, Department of Urology, University of California, San Francisco Medical Center, San Francisco, California*

The molecular and clinical understanding of erectile function continues to gain ground at a particularly fast rate. Advances in gene discovery have aided greatly in working knowledge of smooth muscle relaxation/contraction pathways. Intensive research has yielded many advances. The understanding of the nitric oxide pathway has aided not only in the molecular understanding of the tumescence but also aided greatly in the therapy of erectile dysfunction. As a man ages or undergoes surgery, preventative therapies to preserve erectile function have begun. All clinical interventions derived their beginning in a full anatomical, molecular, and dynamic knowledge base of erectile function and dysfunction. In this chapter the components of erectile function will be explained.

Hemodynamics and Mechanism of Erection and Detumescence

Corpora Caverosa

The penile erectile tissue, specifically the cavernous smooth musculature and the smooth muscles of the arteriolar and arterial walls, plays a key role in the erectile process. In the flaccid state, these smooth muscles are tonically contracted, allowing only a small amount of arterial flow for nutritional purposes. The blood partial pressure of oxygen (PO₂) is about 35mmHg range.¹ The flaccid penis is in a moderate state of contraction, as evidenced by further shrinkage in cold weather and after phenylephrine injection.

Sexual stimulation triggers release of neurotransmitters from the cavernous nerve terminals. This results in relaxation of these smooth muscles and the following events:

1. Dilatation of the arterioles and arteries by increased blood flow in both the diastolic and the systolic phases
2. Trapping of the incoming blood by the expanding sinusoids
3. Compression of the subtunical venular plexuses between the tunica albuginea and the peripheral sinusoids, reducing the venous outflow
4. Stretching of the tunica to its capacity, which occludes the emissary veins between the inner circular and the outer longitudinal layers and further decreases the venous outflow to a minimum

^b Corresponding author for proof and reprints: , Tom F. Lue, MD, Professor and Vice Chair, Emil Tanagho Endowed Chair, Department of Urology, UCSF, 400, Parnassus Avenue, A633, San Francisco, CA 94143-0738, Tel: 415 476 1611, Fax: 415 476 8849, tlue@urol.ucsf.edu

^a Coauthor address: Robert C. Dean, MD, Clinical Fellow, Department of Urology, UCSF, 400 Parnassus Ave Suite A610, San Francisco, California 94143-0738 Tel: (415) 353-2200rdean@urol.ucsf.edu

5. An increase in PO₂ (to about 90 mmHg) and intracavernous pressure (around 100 mm Hg), which raises the penis from the dependent position to the erect state (the full-erection phase)
6. A further pressure increase (to several hundred millimeters of mercury) with contraction of the ischiocavernosus muscles (rigid-erection phase)

The angle of the erect penis is determined by its size and its attachment to the puboischial rami (the crura) and the anterior surface of the pubic bone (the suspensory and funiform ligaments). In men with a long heavy penis or a loose suspensory ligament, the angle usually will not be greater than 90 degrees, even with full rigidity.

Three phases of detumescence have been reported in an animal study.² The first entails a transient intracorporeal pressure increase, indicating the beginning of smooth muscle contraction against a closed venous system. The second phase shows a slow pressure decrease, suggesting a slow reopening of the venous channels with resumption of the basal level of arterial flow. The third phase shows a fast pressure decrease with fully restored venous outflow capacity.

Erection thus involves sinusoidal relaxation, arterial dilatation, and venous compression.³ The importance of smooth muscle relaxation has been demonstrated in animal and human studies.^{4, 5}

Corpus Spongiosum and Glans Penis

The hemodynamics of the corpus spongiosum and glans penis are somewhat different from those of the corpora cavernosa. During erection, the arterial flow increases in a similar manner; however, the pressure in the corpus spongiosum and glans is only one third to one half of that in the corpora cavernosa because the tunical covering (thin over the corpus spongiosum and virtually absent over the glans) ensures minimal venous occlusion. During the full-erection phase, partial compression of the deep dorsal and circumflex veins between Buck's fascia and the engorged corpora cavernosa contribute to glanular tumescence, although the spongiosum and glans essentially function as a large arteriovenous shunt during this phase. In the rigid-erection phase, the ischiocavernosus and bulbocavernosus muscles forcefully compress the spongiosum and penile veins, which results in further engorgement and increased pressure in the glans and spongiosum.

Neuroanatomy and Neurophysiology of Penile Erection

Peripheral Pathways

The innervation of the penis is both autonomic (sympathetic and parasympathetic) and somatic (sensory and motor). From the neurons in the spinal cord and peripheral ganglia, the sympathetic and parasympathetic nerves merge to form the cavernous nerves, which enter the corpora cavernosa and corpus spongiosum to affect the neurovascular events during erection and detumescence. The somatic nerves are primarily responsible for sensation and the contraction of the bulbocavernosus and ischiocavernosus muscles.

Autonomic Pathways

The sympathetic pathway originates from the 11th thoracic to the 2nd lumbar spinal segments and passes through the white rami to the sympathetic chain ganglia. Some fibers then travel through the lumbar splanchnic nerves to the inferior mesenteric and superior hypogastric plexuses, from which fibers travel in the hypogastric nerves to the pelvic plexus. In humans,

the T10 to T12 segments are most often the origin of the sympathetic fibers, and the chain ganglia cells projecting to the penis are located in the sacral and caudal ganglia.⁶

The parasympathetic pathway arises from neurons in the intermediolateral cell columns of the second, third, and fourth sacral spinal cord segments. The preganglionic fibers pass in the pelvic nerves to the pelvic plexus, where they are joined by the sympathetic nerves from the superior hypogastric plexus. The cavernous nerves are branches of the pelvic plexus that innervate the penis. Other branches of the pelvic plexus innervate the rectum, bladder, prostate, and sphincters. The cavernous nerves are easily damaged during radical excision of the rectum, bladder, and prostate. A clear understanding of the course of these nerves is essential to the prevention of iatrogenic ED.⁷ Human cadaveric dissection revealed medial and lateral branches of the cavernous nerves (the former accompany the urethra and the latter pierce the urogenital diaphragm 4 to 7 mm lateral to the sphincter) and multiple communications between the cavernous and the dorsal nerves.⁸

Stimulation of the pelvic plexus and the cavernous nerves induces erection, whereas stimulation of the sympathetic trunk causes detumescence. This clearly implies that the sacral parasympathetic input is responsible for tumescence and the thoracolumbar sympathetic pathway is responsible for detumescence. In experiments with cats and rats, removal of the spinal cord below L4 or L5 reportedly eliminated the reflex erectile response but placement with a female in heat or electrical stimulation of the medial preoptic area produced marked erection.^{9, 10} Paick and Lee also reported that apomorphine-induced erection is similar to psychogenic erection in the rat and can be induced by means of the thoracolumbar sympathetic pathway in case of injury to the sacral parasympathetic centers.¹¹ In man, many patients with sacral spinal cord injury retain psychogenic erectile ability even though reflexogenic erection is abolished. These cerebrally elicited erections are found more frequently in patients with lower motoneuron lesions below T12.¹² No psychogenic erection occurs in patients with lesions above T9; the efferent sympathetic outflow is thus suggested to be at the levels T11 and T12.¹³ Also reported, in these patients with psychogenic erections, lengthening and swelling of the penis are observed but rigidity is insufficient.

It is, therefore, possible that cerebral impulses normally travel through sympathetic (inhibiting norepinephrine release), parasympathetic (releasing NO and acetylcholine), and somatic (releasing acetylcholine) pathways to produce a normal rigid erection. In patients with a sacral cord lesion, the cerebral impulses can still travel by means of the sympathetic pathway to inhibit norepinephrine release, and NO and acetylcholine can still be released through synapse with postganglionic parasympathetic and somatic neurons. Because the number of synapses between the thoracolumbar outflow and the postganglionic parasympathetic and somatic neurons is less than the sacral outflow, the resulting erection will not be as strong.

Somatic Pathways

The somatosensory pathway originates at the sensory receptors in the penile skin, glans, and urethra and within the corpus cavernosum. In the human glans penis are numerous afferent terminations: free nerve endings and corpuscular receptors with a ratio of 10:1. The free nerve endings are derived from thin myelinated A_δ and unmyelinated C fibers and are unlike any other cutaneous area in the body.¹⁴ The nerve fibers from the receptors converge to form bundles of the dorsal nerve of the penis, which joins other nerves to become the pudendal nerve. The latter enters the spinal cord via the S2--S4 roots to terminate on spinal neurons and interneurons in the central gray region of the lumbosacral segment.¹⁵ Activation of these sensory neurons sends messages of pain, temperature, and touch by means of spinothalamic and spinoreticular pathways to the thalamus and sensory cortex for sensory perception. The dorsal nerve of the penis used to be regarded as a purely somatic nerve; however, nerve bundles

testing positive for nitric oxide synthase (NOS), which is autonomic in origin, have been demonstrated in the human by Burnett et al. and in the rat by Carrier and coworkers.^{16, 17} Giuliano and associates have also shown that stimulation of the sympathetic chain at the L4--L5 level elicits an evoked discharge on the dorsal nerve of the penis and stimulation of the dorsal nerve evokes a reflex discharge in the lumbosacral sympathetic chain of rats.¹⁸ These findings clearly demonstrate that the dorsal nerve is a mixed nerve with both somatic and autonomic components that enable it to regulate both erectile and ejaculatory function.

Onuf's nucleus in the second to fourth sacral spinal segments is the center of somatomotor penile innervation. These nerves travel in the sacral nerves to the pudendal nerve to innervate the ischiocavernosus and bulbocavernosus muscles. Contraction of the ischiocavernosus muscles produces the rigid-erection phase. Rhythmic contraction of the bulbocavernosus muscle is necessary for ejaculation. In animal studies, direct innervation of the sacral spinal motoneurons by brain stem sympathetic centers (A5-catecholaminergic cell group and locus coeruleus) has been identified.¹⁹ This adrenergic innervation of pudendal motoneurons may be involved in rhythmic contractions of perineal muscles during ejaculation. In addition, oxytocinergic and serotonergic innervation of lumbosacral nuclei controlling penile erection and perineal muscles in the male rat has also been demonstrated.²⁰

Depending on the intensity and nature of genital stimulation, several spinal reflexes can be elicited by stimulation of the genitalia. The best known is the bulbocavernosus reflex, which is the basis of genital neurologic examination and electrophysiologic latency testing. Although impairment of bulbocavernosus and ischiocavernosus muscles may impair penile erection, the significance of obtaining a bulbocavernosus reflex in overall sexual dysfunction assessment is controversial.

Supraspinal Pathways and Centers

Studies in animals have identified the medial preoptic area (MPOA) and the paraventricular nucleus (PVN) of the hypothalamus and hippocampus as important integration centers for sexual function and penile erection: electrostimulation of this area induces erection, and lesions at this site limit copulation.^{21, 22} Marson et al. injected pseudo-rabies virus into the rat corpus cavernosum and traced labeled neurons from major pelvic ganglia to neurons in the spinal cord, brain stem and hypothalamus.²² Mallick and coworkers also showed that stimulation of the dorsal nerve of the penis in the rat influenced the firing rate of about 80% of the neurons in the MPOA but not in other areas of the hypothalamus.²³ Efferent pathways from the MPOA enter the medial forebrain bundle and the midbrain tegmental region (near the substantia nigra). Pathologic processes in these regions, such as Parkinson's disease or cerebrovascular accidents, are often associated with erectile dysfunction. Axonal tracing in monkeys, cats and rats has shown direct projection from hypothalamic nuclei to the lumbosacral autonomic erection centers. The neurons in these hypothalamic nuclei contain peptidergic neurotransmitters, including oxytocin and vasopressin, which may be involved in penile erection.²¹ Several brain stem and medullary centers are also involved in sexual function. The A5 catecholamine cell group and locus ceruleus have been shown to provide adrenergic innervation to hypothalamus, thalamus, neocortex and spinal cord. Projections from the nucleus paragigantocellularis, which provides inhibitory serotonergic innervation, have also been demonstrated in hypothalamus, the limbic system, the neocortex and the spinal cord.

Central Neural Activation during Sexual Arousal

Positron emission tomography (PET) and functional MRI (fMRI) have allowed a greater understanding of brain activation during human sexual arousal. PET and fMRI scanning measure increases in regional cerebral blood flow or changes in regional cerebral activity

during a particular moment in time. Using this technology, sexual arousal is triggered in young heterosexual male subjects with sexually explicit pictures or videos. Scanned brain images taken during sexual arousal are compared to images taken when the male participants are shown sexually neutral images (relaxation, documentary, or humorous video clips). Brain activation centers as well as deactivation regions can be demonstrated. Although the simplicity of these study designs is elegant, multiple factors are involved in sexual arousal especially arousal triggered by visual clues. The authors of these studies have placed many necessary conditions in an attempt to standardize the methods and participants; however, the complexity of human emotion and sexual response is extremely difficult to regulate.

In 1999, Stoleru et al. studied eight healthy right-handed heterosexual males with PET during visually evoked sexual arousal.²⁴ Regions of brain activation were correlated with testosterone plasma levels and penile tumescence. Significant activation during visual evoked sexual arousal was seen in bilateral inferior temporal cortex, right insula, right inferior frontal cortex, and left anterior cingulate cortex. From this landmark study a tentative model for brain function during sexual arousal was introduced. The model suggests that there are three components of visually evoked sexual arousal associated with their neuroanatomical regions: 1) a perceptual-cognitive component – assesses the visual stimuli as sexual performed in bilateral inferior temporal cortex, 2) a emotional/motivational component – processes sensory information with motivational states performed in the right insula, right inferior frontal cortex and left cingulate cortex (paralimbic areas), 3) a physiological component – coordinates the endocrine and autonomic functions in the left anterior cingulate cortex.

Further investigations were performed using the sexually visual stimuli and PET scanning. Bocher et al. demonstrated increased activation in the inferior lateral occipital cortex, bilateral posterior temporal cortices (right greater than left), right inferior lateral pre-frontal cortex, left post-central gyrus, bilateral inferior parietal lobules, left superior parietal lobules, frontal pole (Brodmann area 10), left pre-frontal cortex, and midbrain regions.²⁵ Bocher also noted deactivation in the medial frontal and anterior cingulate, contrary to Stoleru's report. Again, visual association centers were noted to be activated, in particular posterior temporal cortices and the post-central gyrus. Interestingly, the midbrain activation seen in this study correlates to the location of the dopaminergic neurons. The activation of the midbrain region was not demonstrated in other studies. This activation may be associated with prolonged provocation. The visual sexual stimulus used in this study was a 30-minute continuous video clip. Other studies use brief visual sexual stimuli (2–10 minutes).

Park et al. studied 12 healthy male participants using fMRI.²⁶ Viewing sexual erotic film clips were alternated with non-erotic clips. Regional brain activation was generally seen in the inferior frontal lobe, cingulate gyrus, insular gyrus, corpus collosum, thalamus, caudate nucleus, globus pallidus and inferior temporal lobes. Some activation regions were similar to other studies, in particular the inferior frontal lobes, inferior temporal lobes and the insular gyrus.

In a well-designed study using fMRI and visual evoked stimuli correlated with penile turgidity, Arnov et al. demonstrated a significant region of activation in the right subinsular/insula region including the claustrum.²⁷ Activation of this region is similarly seen in past studies using PET.^{24, 28} This region has been associated with sensory processing. Activation of the insula in this study may represent somatosensory processing and recognition of erection. Other brain regions that were activated during visual sexual stimuli were: right middle gyrus, right temporal gyrus, left caudate and putamen, bilateral cingulate gyri, right sensimotor and pre-motor regions. Also, a smaller activation was seen in the right hypothalamus. Dopamine is projected to the hypothalamus and the evidence that dopamine facilitates male sexual behavior is

substantial. Again, the right middle temporal gyrus is seen activated. It is probably associated with visual processing.

In 2003, Mouras et al. studied 8 men using fMRI; however, video clips were not used.²⁹ Instead still photographs (neutral and sexually arousing) were shown quickly to participants. Using shorter visual sexual stimuli, they believed early neural responses would be generated instead of neural responses to the perception of penile tumescence. Again, activation of the middle and inferior occipital gyri was demonstrated, most likely linked to the visual stimuli not necessarily the sexual component. In addition to multiple brain centers that showed activation with visual sexual stimuli (bilateral parietal lobules, left inferior parietal lobule, right postcentral gyrus, right parietoccipital sulcus, left superior occipital gyrus, bilateral precentral gyrus), the cerebellum demonstrated activation in 3 subjects and deactivation in 4 subjects. Multiple other reports have demonstrated activation of the cerebellum in response to erotic films and viewing pictures of love partners. Therefore, it appears that visual sexual stimuli create activation in regions within the cerebellum.

With the advances with fMRI, detailed comparisons of brain activation in response to visual sexual stimuli has been performed on varied groups. Stoleru et al. studies healthy male subjects as compared to men with hypoactive sexual desire disorder (HSDD).³⁰ The left gyrus rectus, a portion of the medial orbitofrontal cortex remained activated in men with HSDD, which contrasts with its deactivation in healthy men in response to visual sexual stimuli. This region is believed to mediate inhibitory control of motivated behavior. Continued activation of this region may help explain the pathophysiology of HSDD. Montorsi et al. compared men with psychogenic erectile dysfunction (ED) and potent controls following the administration of apomorphine.³¹ In men with psychogenic ED extended activation of the cingulate gyrus, frontal mesial and frontal basal cortex was seen during visual sexual stimuli. This extended activation may suggest an underlying organic etiology for psychogenic ED. With the administration of apomorphine, the fMRI image in psychogenic ED patients was similar to the potent controls. Apomorphine caused additional activation of foci in the psychogenic ED patient (seen in the nucleus accumbens, hypothalamus, mesencephalon). Also the right hemisphere was significantly more activated than the left following apomorphine administration. Right greater left hemisphere activation is a common finding within sexually evoked brain activation studies.

Brain scanning with PET and fMRI has become a powerful tool in the study of central activation of sexual arousal. Many brain regions of activation have been demonstrated in these reports. Some common brain centers of activation can now be described through these reports (Table 1). Psychogenic ED, premature ejaculation, sexual deviations, orgasmic dysfunction are just a few conditions that may have alterations in higher brain function and perhaps now can be studied. As we begin to understand the brain function within normal sexual response and arousal, the cause of the sexual dysfunction conditions may become elucidated.

In summary, the structures above are responsible for the three types of erection: psychogenic, reflexogenic and nocturnal. Psychogenic erection is a result of audiovisual stimuli or fantasy. Impulses from the brain modulate the spinal erection centers (T₁₁-L₂ and S₂-S₄) to activate the erectile process. Reflexogenic erection is produced by tactile stimuli to the genital organs. The impulses reach the spinal erection centers; some then follow the ascending tract, resulting in sensory perception, while others activate the autonomic nuclei to send messages via the cavernous nerves to the penis to induce erection. This type of erection is preserved in patients with upper spinal cord injury. Nocturnal erection occurs mostly during rapid-eye-movement (REM) sleep. PET scanning of humans in REM sleep show increased activity in the pontine area, the amygdala and the anterior cingulate gyrus but decreased activity in the prefrontal

and parietal cortex. The mechanism that triggers REM sleep is located in the pontine reticular formation. During REM sleep, the cholinergic neurons in the lateral pontine tegmentum are activated while the adrenergic neurons in the locus ceruleus and the serotonergic neurons in the midbrain raphe are silent. This differential activation may be responsible for the nocturnal erections during REM sleep.

Molecular Mechanism of Smooth Muscle Contraction and Relaxation

Smooth muscle contraction and relaxation is regulated by cytosolic (sarcolemmic) free Ca^{2+} . Norepinephrine from nerve endings and endothelins and prostaglandin $\text{F}_2\alpha$ from endothelium activate receptors on smooth muscle cells to increase inositol triphosphate and diacylglycerol resulting in release of calcium from intracellular stores such as sarcoplasmic reticulum and/or opening of calcium channels on the smooth muscle cell membrane leading to an influx of calcium from extracellular space. This triggers a transient increase in cytosolic free Ca^{2+} from a resting level of 120 to 270 to 500 to 700 nM.³² At the elevated level, Ca^{2+} binds to calmodulin and changes the latter's conformation to expose sites of interaction with myosin light-chain kinase. The resultant activation catalyzes phosphorylation of myosin light chains and triggers cycling of myosin crossbridges (heads) along actin filaments and the development of force. In addition, phosphorylation of the light chain also activates myosin ATPase, which hydrolyzes ATP to provide energy for muscle contraction (Figure 1).

Once the cytosolic Ca^{2+} returns the basal levels, the calcium-sensitizing pathways take over. One such mechanism is via activation of excitatory receptors coupled to G-proteins which can also cause contraction by increasing calcium sensitivity without any change in cytosolic Ca^{2+} . This pathway involves RhoA, a small, monomeric G protein that activates Rho-kinase. Activated Rho-kinase phosphorylates and thereby inhibits the regulatory subunit of smooth muscle myosin phosphatase preventing dephosphorylation of myofilaments thus maintain contractile tone (Figure 2).³³

RhoA and Rho-kinase have been shown to be expressed in penile smooth muscle.^{34, 35} Interestingly, the amount of RhoA expressed in the cavernosal smooth muscle is 17 fold higher than in the vascular smooth muscle.³⁵ A selective inhibitor of Rho-kinase has been shown to elicit relaxation of human corpus cavernosum in vitro and to induce penile erection in animal models.³⁶ Anesthetized rats transfected with dominant negative RhoA exhibited an elevated erectile function as compared with control animals.³⁷ The emerging consensus is that the phasic contraction of penile smooth muscle is regulated by an increase in cytosolic Ca^{2+} and the tonic contraction is governed by the calcium sensitizing pathways.³⁸

In addition to the central role of myosin phosphorylation in smooth muscle contraction, other mechanisms may modulate or fine-tune the contractile state. For example, caldesmon may be involved in the latch state in which the force of contraction is maintained at a low level of myosin phosphorylation and with a low energy expenditure.

Relaxation of the muscle follows a decrease of free Ca^{2+} in the sarcoplasm. Calmodulin then dissociates from myosin light-chain kinase and inactivates it. Myosin is dephosphorylated by myosin light-chain phosphatase and detaches from the actin filament, and the muscle relaxes.³² Others suggest that the NO-cGMP inhibitory pathway in corpus cavernosum smooth muscle is not simply a reversal of excitatory signal transduction mechanisms; an unidentified mechanism may contribute to relaxation by decreasing the rate of crossbridge recruitment through phosphorylation.

cAMP and cGMP are the second messengers involved in smooth muscle relaxation. They activate cAMP- and cGMP-dependent protein kinases, which in turn phosphorylate certain

proteins and ion channels, resulting in (1) opening of the potassium channels and hyperpolarization; (2) sequestration of intracellular calcium by the endoplasmic reticulum; and (3) inhibition of voltage-dependent calcium channels, blocking calcium influx. The consequence is a drop in cytosolic free calcium and smooth muscle relaxation (Figure 3).

Pathophysiology of Erectile Dysfunction

Classification

Many classifications have been proposed for ED. Some are based on the cause (diabetic, iatrogenic, traumatic) and some on the neurovascular mechanism of the erectile process (failure to initiate [neurogenic], failure to fill [arterial], and failure to store [venous]). A classification recommended by the International Society of Impotence Research is shown in Table 2.³⁹

Psychogenic

Previously, psychogenic impotence was believed to be the most common type, with 90% of impotent men thought to suffer from this condition.⁴⁰ This belief has given way to the realization that most men with ED have a mixed condition that may be either predominantly functional or predominantly physical.

Sexual behavior and penile erection are controlled by the hypothalamus, the limbic system, and the cerebral cortex. Therefore, stimulatory or inhibitory messages can be relayed to the spinal erection centers to facilitate or inhibit erection. Two possible mechanisms have been proposed to explain the inhibition of erection in psychogenic dysfunction: direct inhibition of the spinal erection center by the brain as an exaggeration of the normal suprasacral inhibition and excessive sympathetic outflow or elevated peripheral catecholamine levels, which may increase penile smooth muscle tone to prevent the relaxation necessary for erection.⁴¹ Animal studies demonstrate that the stimulation of sympathetic nerves or systemic infusion of epinephrine causes detumescence of the erect penis.^{42, 43} Clinically, higher levels of serum norepinephrine have been reported in patients with psychogenic ED than in normal controls or patients with vasculogenic ED.⁴⁴

Bancroft and Janssen theorized that male sexual response depends on the balance between excitatory and inhibitory impulses within the CNS.⁴⁵ They are testing sexual inhibitory and sexual excitatory questionnaires that may help identify whether a patient will have a more successful outcome with psychotherapy or with pharmacologic treatment.

Neurogenic

It has been estimated that 10 to 19% of ED is of neurogenic origin.^{46, 47} If one includes iatrogenic causes and mixed ED, the prevalence of neurogenic ED is probably much higher. While the presence of a neurologic disorder or neuropathy does not exclude other causes, confirming that ED is neurogenic in origin can be challenging. Because an erection is a neurovascular event, any disease or dysfunction affecting the brain, spinal cord, cavernous and pudendal nerves can induce dysfunction.

The MPOA, the paraventricular nucleus, and the hippocampus have been regarded as important integration centers for sexual drive and penile erection.⁴⁸ Pathologic processes in these regions, such as Parkinson's disease, stroke, encephalitis, or temporal lobe epilepsy, are often associated with ED. Parkinsonism's effect may be caused by the imbalance of the dopaminergic pathways.⁴⁹ Other lesions in the brain noted to be associated with ED are tumors, dementias, Alzheimer's disease, Shy-Drager syndrome, and trauma.

In men with a spinal cord injury, their erectile function depends largely on the nature, location, and extent of the spinal lesion. In addition to ED they may also have impaired ejaculation and orgasm. Reflexogenic erection is preserved in 95% of patients with complete upper cord lesions, whereas only about 25% of those with complete lower cord lesions can achieve an erection.⁵⁰ It appears that sacral parasympathetic neurons are important in the preservation of reflexogenic erection. However, the thoracolumbar pathway may compensate for loss of the sacral lesion through synaptic connections.¹⁰ In these men, minimal tactile stimulation can trigger erection, albeit of short duration, requiring continuous stimulation to maintain erection. Other disorders at the spinal level (e.g., spina bifida, disc herniation, syringomyelia, tumor, transverse myelitis, and multiple sclerosis) may affect the afferent or the efferent neural pathway in a similar manner.

Because of the close relationship between the cavernous nerves and the pelvic organs, surgery on these organs is a frequent cause of impotence. The incidence of iatrogenic impotence from various procedures has been reported as follows: radical prostatectomy, 43% to 100%; perineal prostatectomy for benign disease, 29%; abdominal perineal resection, 15% to 100%; and external sphincterotomy at the 3- and 9-o'clock positions, 2% to 49%.⁵¹⁻⁵⁶

An improved understanding of the neuroanatomy of the pelvic and cavernous nerves has resulted in modified surgery for cancer of the rectum, bladder, and prostate, producing a lower incidence of iatrogenic impotence.⁵³ For example, the introduction of nerve-sparing radical prostatectomy has reduced the incidence of impotence from nearly 100% to 30-50%.^{57, 58} Recovery of erectile function after radical pelvic surgery can take 6 to 24 months. Early treatment with intracavernous alprostadil or oral sildenafil have been shown to improve recovery of erectile function.^{59, 60} It is believed that the pharmacologically- induced erections prevent the structural tissue changes associated with infrequent or no erections during the nerve recovery period.

In cases of pelvic fracture, ED can be a result of cavernous nerve injury or vascular insufficiency or both. In an animal experiment in mature rats, alcoholism, vitamin deficiency, or diabetes may affect the cavernous nerve terminals and may result in deficiency of neurotransmitters. In diabetics, impairment of neurogenic and endothelium-dependent relaxation results in inadequate NO release.⁴ Because there is no direct means to test the autonomic innervation of the penis, clinicians should be cautious in making the diagnosis of neurogenic ED. NADPH diaphorase staining of the NANC nerve fibers in penile biopsy specimens has been proposed as an indicator of neurogenic status.⁶¹ Stief and associates also propose single potential analysis of cavernous electrical activity for assessment of cavernous nerve function.⁶² Further studies are needed before these tests can be used routinely in clinical practice.

Bemelmans and colleagues performed somatosensory evoked potentials and sacral reflex latencies on impotent patients with no clinically overt neurologic disease and found that 47% had at least one abnormal neurophysiologic measurement and that an abnormality was found more often in older patients.⁶³ A decrease in penile tactile sensitivity with increasing age was also reported by Rowland and coworkers.⁶⁴ Sensory input from the genitalia is essential in achieving and maintaining reflexogenic erection, and the input becomes even more important when older people gradually lose psychogenic erection. Therefore, sensory evaluation should be an integral part of the evaluation for ED in all patients with or without an apparent neurologic disorder.

Endocrinologic

Hypogonadism is a not-infrequent finding in the impotent population. Androgens influence the growth and development of the male reproductive tract and secondary sex characteristics;

their effects on libido and sexual behavior are well established. In a review of published articles from 1975 to 1992, Mulligan and Schmitt concluded: (1) testosterone enhances sexual interest; (2) testosterone increases frequency of sexual acts; and (3) testosterone increases the frequency of nocturnal erections but has little or no effect on fantasy-induced or visually induced erections.⁶⁵ A study correlating nocturnal erections and testosterone levels in men, reported that the threshold for normal nocturnal erections is about 200 ng/dl.⁶⁶ Men with lower serum testosterone levels often have abnormal nocturnal erection parameters compared to men with normal levels of testosterone. However, exogenous testosterone therapy in impotent men with borderline low testosterone levels reportedly has little effect on potency.⁶⁷

Several investigators have examined the mechanism of androgen's effect. Beyer and Gonzales-Mariscal have reported that testosterone and dihydrotestosterone are responsible for male pelvic thrusting and estradiol or testosterone for female pelvic thrusting during copulation.⁶⁸ In rats, castration has been reported to decrease arterial flow, induce venous leakage, and reduce about half of the erectile response to stimulation of the cavernous nerve.^{69, 70} Treatment with flutamide, estradiol, or a gonadotropin-releasing hormone antagonist in addition to castration further depresses the erectile response. Although penile NOS activity is reduced in these animals, the contents of neuronal NOS (nNOS) and endothelial NOS (eNOS) are not significantly reduced by the treatment. Castration also increases α -adrenergic responsiveness of penile smooth muscle, increases apoptosis in the corpus cavernosum in the rats, and reduces trabecular smooth muscle content in rabbit.⁷¹⁻⁷³ Clinically, many men on long-term androgen ablation therapy for prostate cancer have reported poor libido and ED.

Any dysfunction of the hypothalamic-pituitary axis can result in hypogonadism. Hypogonadotropic hypogonadism can be congenital or caused by a tumor or injury; hypergonadotropic hypogonadism may result from a tumor, injury or surgery to the testis, or mumps orchitis.

Hyperprolactinemia, whether from a pituitary adenoma or drugs, results in both reproductive and sexual dysfunction. Symptoms may include loss of libido, ED, galactorrhea, gynecomastia, and infertility. Hyperprolactinemia is associated with low circulating levels of testosterone, which appear to be secondary to inhibition of gonadotropin-releasing hormone secretion by the elevated prolactin levels.⁷⁴

ED also may be associated with both the hyperthyroid and the hypothyroid state. Hyperthyroidism is commonly associated with diminished libido, which may be caused by the increased circulating estrogen levels, and less often with ED. In hypothyroidism, low testosterone secretion and elevated prolactin levels contribute to ED.

Arteriogenic

Atherosclerotic or traumatic arterial occlusive disease of the hypogastric-cavernous-helicine arterial tree can decrease the perfusion pressure and arterial flow to the sinusoidal spaces, thus increasing the time to maximal erection and decreasing the rigidity of the erect penis. In the majority of patients with arteriogenic ED, the impaired penile perfusion is a component of the generalized atherosclerotic process. Michal and Ruzbarsky found that the incidence and age at onset of coronary disease and ED are parallel.⁷⁵ Common risk factors associated with arterial insufficiency include hypertension, hyperlipidemia, cigarette smoking, diabetes mellitus, blunt perineal or pelvic trauma, and pelvic irradiation.⁷⁶⁻⁷⁸ Shabsigh and associates reported that abnormal penile vascular findings increased significantly as the number of risk factors for ED increased.⁷⁹ On arteriography, bilateral diffuse disease of the internal pudendal, common penile, and cavernous arteries has been found in impotent patients with atherosclerosis. Focal stenosis of the common penile or cavernous artery is most often seen in young patients who

have sustained blunt pelvic or perineal trauma.⁷⁷ Long-distance cycling is also a risk factor for vasculogenic and neurogenic ED.^{80, 81}

In one report, diabetic men and older men had a high incidence of fibrotic lesions of the cavernous artery, with intimal proliferation, calcification, and luminal stenosis.⁷⁵ Nicotine may adversely affect erectile function not only by decreasing arterial flow to the penis but also by blocking corporeal smooth muscle relaxation and thus preventing normal venous occlusion.^{82, 83}

Erectile dysfunction and cardiovascular disease share the same risk factors such as hypertension, diabetes mellitus, hypercholesterolemia and smoking.^{84, 85} Lesions in the pudendal arteries are much more common in impotent men than in general population of similar age.⁸⁶ Therefore erectile dysfunction can be a manifestation of generalized or focal arterial disease.⁸⁷

Mechanism of Arteriogenic ED

1. Structural Changes—In ED due to arterial insufficiency, there is a decrease in oxygen tension in corpus cavernosum blood compared to that measured in patients with psychogenic ED.⁸⁸ Since PGE1 and PGE2 formation is oxygen-dependent, an increase in oxygen tension is associated with elevation of PGE2 and suppression of TGF- β 1-induced collagen synthesis in rabbit and human corpus cavernosum.^{89, 90} Conversely, a decrease in oxygen tension may diminish cavernous trabecular smooth muscle content and lead to diffuse venous leakage.^{91, 92}

A narrowed lumen or increased wall to lumen ratio in the arteries contributes to increased peripheral vascular resistance in hypertension.⁹³ An increased resistance was also found in the penile vasculature of spontaneously hypertensive rats (SHR), and these alterations were ascribed to structural changes of the arterial and erectile tissue.^{94–96} The increase in extracellular matrix expansion affects both interstitium and neural structures of the penis.

2. Vasoconstriction—Enhanced basal and myogenic tone has been observed in arteries from hypertensive rats. Enhanced sympathetic nerve activity accompanies hypertension has also been reported in man and hypertensive animals.^{97, 98} The enhanced vasoconstriction of the penile vasculature in SHR induced by infusion of phenylephrine was attributed to hypertrophy of the vascular wall but not the alteration of sympathetic neurotransmitters.⁹⁴

3. Impaired Endothelium-dependent Vasodilatation—In patients with essential hypertension, endothelium-dependent vasodilatation elicited by infusion of agonists such as acetylcholine, bradykinin, or flow, is diminished.^{99–101} Recent evidence indicates that profound endothelial dysfunction in the coronary circulation can predict major coronary events.^{102, 103} Endothelial dysfunction measured as blunted acetylcholine-induced vasorelaxation is evident in small arteries from patients with renovascular hypertension.^{104, 105} However, there is a lack of study of penile endothelial function in hypertensive men.

In the SHR, the relaxing effect of acetylcholine is blunted both in large and in small arteries, and endothelial dysfunction appears to develop with the appearance of hypertension.¹⁰⁶ Endothelium-dependent relaxation evoked by acetylcholine is also impaired in corporal strips from SHR and these relaxations are restored in the presence of indomethacin.¹⁰⁷ Impairment of endothelium-dependent relaxation could be ascribed to angiotensin II thromboxane and superoxide in arteries from SHR or high blood pressure per se.^{108–112}

Cavernosal (Venogenic)

Failure of adequate venous occlusion has been proposed as one of the most common causes of vasculogenic impotence.¹¹³ Venocclusive dysfunction may result from the following pathophysiologic processes:

1. The presence or development of large venous channels draining the corpora cavernosa.
2. Degenerative changes (Peyronie's disease, old age, and diabetes) or traumatic injury to the tunica albuginea (penile fracture) resulting in inadequate compression of the subtunica and emissary veins. In Peyronie's disease, the inelastic tunica albuginea may prevent the emissary veins from closing.¹¹⁴ Iacono and coworkers have postulated that a decrease in elastic fibers in the tunica albuginea and an alteration of microarchitecture may contribute to impotence in some men.^{115, 116} Changes in the subtunica areolar layer may impair the venocclusive mechanism, as is occasionally seen in patients after surgery for Peyronie's disease.¹¹⁷
3. Structural alterations in the fibroelastic components of the trabeculae, cavernous smooth muscle, and endothelium may result in venous leak.
4. Insufficient trabecular smooth muscle relaxation, causing inadequate sinusoidal expansion and insufficient compression of the subtunica venules, may occur in an anxious individual with excessive adrenergic tone or in a patient with inadequate neurotransmitter release. It has been shown that alteration of an α adrenoceptor or a decrease in NO release may heighten the smooth muscle tone and impair the relaxation in response to endogenous muscle relaxant.¹¹⁸
5. Acquired venous shunts---the result of operative correction of priapism---may cause persistent glans/cavernosum or cavernosum/spongiosum shunting.

Fibroelastic Component

Loss of compliance of the penile sinusoids associated with increased deposition of collagen and decreased elastic fibers may be seen in diabetes, hypercholesterolemia, vascular disease, penile injury, or old age.^{119, 120} Sattar and coworkers reported a significant difference in the mean percentage of elastic fibers in the penis: 9% in normal men, 5.1% in patients with venous leakage, and 4.3% in patients with arterial disease.¹²¹ In an animal model of vasculogenic ED, Nehra and associates demonstrated that cavernosal expandability correlates with smooth muscle content and may be used to predict trabecular histology.⁹² Moreland and colleagues have shown that prostaglandin E₁ suppresses collagen synthesis by transforming growth factor- β 1 in human cavernous smooth muscle, which implies that intracavernous injection of prostaglandin E₁ may be beneficial in preventing intracavernous fibrosis.⁸⁹

Smooth Muscle

Because corporeal smooth muscle controls the vascular event leading to erection, change of smooth muscle content and ultrastructure can be expected to affect erectile response. In a study of human penile tissue, Sattar and associates demonstrated a significant difference between the mean percentage of cavernous smooth muscle in normal potent men, stained with antidesmin (38.5%) or antiactin (45.2%), and that in the venous group (antidesmin, 27.4%; antiactin, 34.2%) or the arteriogenic group (antidesmin, 23.7%, antiactin, 28.9%).¹²¹ An in vitro biochemical study has shown impaired neurogenic and endothelium-related relaxation of penile smooth muscle in impotent diabetic men.⁴ In vasculogenic and neurogenic ED, the damaged smooth muscle can be a key factor, aggravating the primary cause.¹²² Pickard and coworkers have also shown impairment of nerve-evoked relaxation and α -adrenergic—

stimulated contraction of cavernous muscle as well as reduced muscle content in men with venous or mixed venous/arterial impotence.¹²³

Ion channels are intimately involved in the biochemical events of muscle function, and an alteration of ion channels may have a profound effect on muscle function. Fan and associates reported an alteration of the maxi-K⁺ channel in cells from impotent patients and suggested that impairment in the function or regulation of potassium channels might contribute to the decreased hyperpolarizing ability, altered calcium homeostasis, and impaired smooth muscle relaxation in impotence patients.¹²⁴ In animal studies, Junemann and associates showed significant smooth muscle degeneration with loss of cell-to-cell contact in rabbits fed a high-cholesterol diet for 3 months.⁸² In a rabbit model of vasculogenic impotence, Azadzoï and associates demonstrated that veno-occlusive dysfunction could be induced by cavernosal ischemia.¹²⁵

Gap Junction

These intercellular communication channels are responsible for the synchronized and coordinated erectile response, although their pathophysiologic impact has yet to be clarified.^{126, 127} In severe arterial disease, a loss or reduction of membrane contact is seen because of the presence of collagen fibers between cellular membranes.¹²⁸ These findings imply that a malfunction or loss of gap junctions may alter the coordinated smooth muscle activity.

Endothelium

By release of vasoactive agents, the endothelium of the corpus cavernosum can modify the tone of adjacent smooth muscle and affect the development or inhibition of an erection. NO, prostaglandin, and the polypeptide endothelins have been identified in the endothelial cell.^{5, 91} Activation of cholinergic receptors on the endothelial cell by acetylcholine or stretching of the endothelial cells as a result of increased blood flow may elicit underlying smooth muscle relaxation through the release of NO. Diabetes and hypercholesterolemia have been shown to alter the function of endothelium-mediated relaxation of the cavernous muscle and impair erection.¹²⁹

In summary, considerable events can cause erectile dysfunction. In addition no one cause may be involved independently. A cascade of issues (including psychological as well as organic) can lead the to the impotent state. A continued understanding of the organic causes of erectile dysfunction will allow the physician to discover therapies for correction as well as provide reassurance to the patient.

References

1. Sattar AA, Salpigidis G, Vanderhaeghen JJ, et al. Cavernous oxygen tension and smooth muscle fibers: relation and function. *J Urol* 1995;154:1736. [PubMed: 7563335]
2. Bosch RJ, Benard F, Aboseif SR, et al. Penile detumescence: characterization of three phases. *J Urol* 1991;146:867. [PubMed: 1875515]
3. Lue TF, Takamura T, Schmidt RA, et al. Hemodynamics of erection in the monkey. *J Urol* 1983;130:1237. [PubMed: 6417346]
4. Saenz de Tejada I, Goldstein I, Azadzoï K, et al. Impaired neurogenic and endothelium-mediated relaxation of penile smooth muscle from diabetic men with impotence. *N Engl J Med* 1989;320:1025. [PubMed: 2927481]
5. Ignarro LJ, Bush PA, Buga GM, et al. Nitric oxide and cyclic GMP formation upon electrical field stimulation cause relaxation of corpus cavernosum smooth muscle. *Biochem Biophys Res Commun* 1990;170:843. [PubMed: 2166511]
6. De Groat, W, Booth A. Neural control of penile erection. London: Harwood, pp. 465–513, 1993

7. Walsh PC, Brendler CB, Chang T, et al. Preservation of sexual function in men during radical pelvic surgery. *Md Med J* 1990;39:389. [PubMed: 2333025]
8. Paick JS, Donatucci CF, Lue TF. Anatomy of cavernous nerves distal to prostate: microdissection study in adult male cadavers. *Urology* 1993;42:145. [PubMed: 8367921]
9. Root W, Bard P. The mediation of feline erection through sympathetic pathways with some reference on sexual behavior after deafferentation of the genitalia. *Am J Physiol* 1947;151:80.
10. Courtois FJ, Macdougall JC, Sachs BD. Erectile mechanism in paraplegia. *Physiol Behav* 1993;53:721. [PubMed: 8511177]
11. Paick JS, Lee SW. The neural mechanism of apomorphine-induced erection: an experimental study by comparison with electrostimulation-induced erection in the rat model. *J Urol* 1994;152:2125. [PubMed: 7966700]
12. Bors E, Camarr A. Neurological disturbances in sexual function with special reference to 529 patients with spinal cord injury. *Urol Surv* 1960;10:191.
13. Chapelle PA, Durand J, Lacert P. Penile erection following complete spinal cord injury in man. *Br J Urol* 1980;52:216. [PubMed: 7426981]
14. Halata Z, Munger BL. The neuroanatomical basis for the protopathic sensibility of the human glans penis. *Brain Res* 1986;371:205. [PubMed: 3697758]
15. McKenna KE. Central control of penile erection. *Int J Impot Res* 1998;10 (Suppl 1):S25. [PubMed: 9669218]
16. Burnett AL, Tillman SL, Chang TS, et al. Immunohistochemical localization of nitric oxide synthase in the autonomic innervation of the human penis. *J Urol* 1993;150:73. [PubMed: 7685426]
17. Carrier S, Zvara P, Nunes L, et al. Regeneration of nitric oxide synthase-containing nerves after cavernous nerve neurotomy in the rat. *J Urol* 1995;153:1722. [PubMed: 7536273]
18. Giuliano F, Rampin O, Jardin A, et al. Electrophysiological study of relations between the dorsal nerve of the penis and the lumbar sympathetic chain in the rat. *J Urol* 1993;150:1960. [PubMed: 8230545]
19. Marson L, McKenna KE. CNS cell groups involved in the control of the ischiocavernosus and bulbospongiosus muscles: a transneuronal tracing study using pseudorabies virus. *J Comp Neurol* 1996;374:161. [PubMed: 8906491]
20. Tang Y, Rampin O, Calas A, et al. Oxytocinergic and serotonergic innervation of identified lumbosacral nuclei controlling penile erection in the male rat. *Neuroscience* 1998;82:241. [PubMed: 9483517]
21. Sachs B, Meisel R. *The physiology of male sexual behavior*. New York: Raven Press, pp. 1393–1423, 1988
22. Marson L, Platt KB, McKenna KE. Central nervous system innervation of the penis as revealed by the transneuronal transport of pseudorabies virus. *Neuroscience* 1993;55:263. [PubMed: 7688882]
23. Mallick HN, Manchanda SK, Kumar VM. Sensory modulation of the medial preoptic area neuronal activity by dorsal penile nerve stimulation in rats. *J Urol* 1994;151:759. [PubMed: 8309001]
24. Stoleru S, Gregoire MC, Gerard D, et al. Neuroanatomical correlates of visually evoked sexual arousal in human males. *Arch Sex Behav* 1999;28:1. [PubMed: 10097801]
25. Bocher M, Chisin R, Parag Y, et al. Cerebral activation associated with sexual arousal in response to a pornographic clip: A 15O-H2O PET study in heterosexual men. *Neuroimage* 2001;14:105. [PubMed: 11525320]
26. Park K, Seo JJ, Kang HK, et al. A new potential of blood oxygenation level dependent (BOLD) functional MRI for evaluating cerebral centers of penile erection. *Int J Impot Res* 2001;13:73. [PubMed: 11426342]
27. Arnow BA, Desmond JE, Banner LL, et al. Brain activation and sexual arousal in healthy, heterosexual males. *Brain* 2002;125:1014. [PubMed: 11960892]
28. Redoute J, Stoleru S, Gregoire MC, et al. Brain processing of visual sexual stimuli in human males. *Hum Brain Mapp* 2000;11:162. [PubMed: 11098795]
29. Mouras H, Stoleru S, Bittoun J, et al. Brain processing of visual sexual stimuli in healthy men: a functional magnetic resonance imaging study. *Neuroimage* 2003;20:855. [PubMed: 14568457]

30. Stoleru S, Redoute J, Costes N, et al. Brain processing of visual sexual stimuli in men with hypoactive sexual desire disorder. *Psychiatry Res* 2003;124:67. [PubMed: 14561426]
31. Montorsi F, Perani D, Anchisi D, et al. Brain activation patterns during video sexual stimulation following the administration of apomorphine: results of a placebo-controlled study. *Eur Urol* 2003;43:405. [PubMed: 12667722]
32. Walsh MP. The Ayerst Award Lecture 1990. Calcium-dependent mechanisms of regulation of smooth muscle contraction. *Biochem Cell Biol* 1991;69:771. [PubMed: 1818584]
33. Somlyo AP, Somlyo AV. Signal transduction by G-proteins, rho-kinase and protein phosphatase to smooth muscle and non-muscle myosin II. *J Physiol* 2000;522(Pt 2):177. [PubMed: 10639096]
34. Rees RW, Ziessen T, Ralph DJ, et al. Human and rabbit cavernosal smooth muscle cells express Rho-kinase. *Int J Impot Res* 2002;14:1. [PubMed: 11896471]
35. Wang H, Eto M, Steers WD, et al. RhoA-mediated Ca²⁺ sensitization in erectile function. *J Biol Chem* 2002;277:30614. [PubMed: 12060659]
36. Rees RW, Ralph DJ, Royle M, et al. Y-27632, an inhibitor of Rho-kinase, antagonizes noradrenergic contractions in the rabbit and human penile corpus cavernosum. *Br J Pharmacol* 2001;133:455. [PubMed: 11399661]
37. Chitale K, Bivalacqua TJ, Champion HC, et al. Adeno-associated viral gene transfer of dominant negative RhoA enhances erectile function in rats. *Biochem Biophys Res Commun* 2002;298:427. [PubMed: 12413959]
38. Celtek S, Rees RW, Kalsi J. A Rho-kinase inhibitor, soluble guanylate cyclase activator and nitric oxide-releasing PDE5 inhibitor: novel approaches to erectile dysfunction. *Expert Opin Investig Drugs* 2002;11:1563.
39. Lizza EF, Rosen RC. Definition and classification of erectile dysfunction: report of the Nomenclature Committee of the International Society of Impotence Research. *Int J Impot Res* 1999;11:141. [PubMed: 10404282]
40. Masters, W Johnson, V. *Human Sexual Response*. Boston: Little Brown, 1970
41. Steers WD. Neural control of penile erection. *Semin Urol* 1990;8:66. [PubMed: 1972291]
42. Diederichs W, Stief CG, Benard F, et al. The sympathetic role as an antagonist of erection. *Urol Res* 1991;19:123. [PubMed: 1853514]
43. Diederichs W, Stief CG, Lue TF, et al. Sympathetic inhibition of papaverine induced erection. *J Urol* 1991;146:195. [PubMed: 2056590]
44. Kim SC, Oh MM. Norepinephrine involvement in response to intracorporeal injection of papaverine in psychogenic impotence. *J Urol* 1992;147:1530. [PubMed: 1593682]
45. Bancroft J. Lecture 4: psychogenic erectile dysfunction-a theoretical approach. *Int J Impot Res* 2000;12 (Suppl 3):S46. [PubMed: 11002401]
46. Abicht J. Testing the autonomic system. In: *Erectile Dysfunction*. Edited by U. Jonas, W. Thoh, C. Steif. Berlin: SpringerVerlag, pp. 187–194, 1991
47. Aboseif S, Shinohara K, Borirakchanyavat S, et al. The effect of cryosurgical ablation of the prostate on erectile function. *Br J Urol* 1997;80:918. [PubMed: 9439410]
48. Sachs B, RL M. The physiology of male sexual behavior. In: *The Physiology of Reproduction*. Edited by E. Knobil, J. Neill, L. Ewing. New York: Raven Press, pp. 1393–1423, 1988
49. Wermuth L, Stenager E. Sexual aspects of Parkinson's disease. *Semin Neurol* 1992;12:125. [PubMed: 1502430]
50. Eardley I, Kirby R. Neurogenic Impotence. In: *Impotence: Diagnosis and Management of Male Erectile Dysfunction*. Edited by R. Kirby, C. Carson, G. Webster. Oxford: Butterworth-Heinemann, pp. 227–231, 1991
51. Veenema RJ, Gursel EO, Lattimer JK. Radical retropubic prostatectomy for cancer: a 20-year experience. *J Urol* 1977;117:330. [PubMed: 839596]
52. Finkle AL, Taylor SP. Sexual potency after radical prostatectomy. *J Urol* 1981;125:350. [PubMed: 7206084]
53. Walsh PC, Donker PJ. Impotence following radical prostatectomy: insight into etiology and prevention. *J Urol* 1982;128:492. [PubMed: 7120554]

54. Weinstein M, Roberts M. Sexual potency following surgery for rectal carcinoma. A followup of 44 patients. *Ann Surg* 1977;185:295. [PubMed: 843127]
55. Yeager ES, Van Heerden JA. Sexual dysfunction following proctocolectomy and abdominoperineal resection. *Ann Surg* 1980;191:169. [PubMed: 7362286]
56. McDermott DW, Bates RJ, Heney NM, et al. Erectile impotence as complication of direct vision cold knife urethrotomy. *Urology* 1981;18:467. [PubMed: 7314336]
57. Catalona WJ, Bigg SW. Nerve-sparing radical prostatectomy: evaluation of results after 250 patients. *J Urol* 1990;143:538. [PubMed: 2304166]
58. Quinlan DM, Epstein JI, Carter BS, et al. Sexual function following radical prostatectomy: influence of preservation of neurovascular bundles. *J Urol* 1991;145:998. [PubMed: 2016818]
59. Montorsi F, Guazzoni G, Strambi LF, et al. Recovery of spontaneous erectile function after nerve-sparing radical retropubic prostatectomy with and without early intracavernous injections of alprostadil: results of a prospective, randomized trial. *J Urol* 1997;158:1408. [PubMed: 9302132]
60. Padma-Nathan H, McCullough A, Forest C. Erectile dysfunction secondary to nerve-sparing radical retropubic prostatectomy: comparative phosphodiesterase-5 inhibitor efficacy for therapy and novel prevention strategies. *Curr Urol Rep* 2004;5:467. [PubMed: 15541217]
61. Brock G, Nunes L, Padma-Nathan H, et al. Nitric oxide synthase: a new diagnostic tool for neurogenic impotence. *Urology* 1993;42:412. [PubMed: 7692661]
62. Stief CG, Djamilian M, Anton P, et al. Single potential analysis of cavernous electrical activity in impotent patients: a possible diagnostic method for autonomic cavernous dysfunction and cavernous smooth muscle degeneration. *J Urol* 1991;146:771. [PubMed: 1875491]
63. Bemelmans BL, Meuleman EJ, Anten BW, et al. Penile sensory disorders in erectile dysfunction: results of a comprehensive neuro-uropsychological diagnostic evaluation in 123 patients. *J Urol* 1991;146:777. [PubMed: 1875492]
64. Rowland DL, Greenleaf WJ, Dorfman LJ, et al. Aging and sexual function in men. *Arch Sex Behav* 1993;22:545. [PubMed: 8285844]
65. Mulligan T, Schmitt B. Testosterone for erectile failure. *J Gen Intern Med* 1993;8:517. [PubMed: 8410427]
66. Granata AR, Rochira V, Lerchl A, et al. Relationship between sleep-related erections and testosterone levels in men. *J Androl* 1997;18:522. [PubMed: 9349750]
67. Graham C, Regan J. Blinded clinical trial of testosterone enanthate in impotent men with low or low-normal serum testosterone levels. *Int J Impot Res* 1992;P144
68. Beyer C, Gonzalez-Mariscal G. Effects of sex steroids on sensory and motor spinal mechanisms. *Psychoneuroendocrinology* 1994;19:517. [PubMed: 7938351]
69. Mills TM, Stopper VS, Wiedmeier VT. Effects of castration and androgen replacement on the hemodynamics of penile erection in the rat. *Biol Reprod* 1994;51:234. [PubMed: 7948478]
70. Penson DF, Ng C, Cai L, et al. Androgen and pituitary control of penile nitric oxide synthase and erectile function in the rat. *Biol Reprod* 1996;55:567. [PubMed: 8862773]
71. Reilly CM, Lewis RW, Stopper VS, et al. Androgenic maintenance of the rat erectile response via a non-nitric-oxide-dependent pathway. *J Androl* 1997;18:588. [PubMed: 9432131]
72. Shabsigh R. The effects of testosterone on the cavernous tissue and erectile function. *World J Urol* 1997;15:21. [PubMed: 9066090]
73. Traish AM, Park K, Dhir V, et al. Effects of castration and androgen replacement on erectile function in a rabbit model. *Endocrinology* 1999;140:1861. [PubMed: 10098525]
74. Leonard MP, Nickel CJ, Morales A. Hyperprolactinemia and impotence: why, when and how to investigate. *J Urol* 1989;142:992. [PubMed: 2795758]
75. Michal V, V R. Histological changes in the penile arterial bed with aging and diabetes. In: *Vasculogenic Impotence: Proceedings of the First International Conference on Corpus Cavernosum Revascularization*. Edited by A. Zorogniotti and G. Rossi. Springfield, IL: Charles C Thomas, pp. 113–119, 1980
76. Goldstein I, Feldman MI, Deckers PJ, et al. Radiation-associated impotence. A clinical study of its mechanism. *Jama* 1984;251:903. [PubMed: 6694291]

77. Levine FJ, Greenfield AJ, Goldstein I. Arteriographically determined occlusive disease within the hypogastric-cavernous bed in impotent patients following blunt perineal and pelvic trauma. *J Urol* 1990;144:1147. [PubMed: 2231888]
78. Rosen MP, Greenfield AJ, Walker TG, et al. Arteriogenic impotence: findings in 195 impotent men examined with selective internal pudendal angiography. Young Investigator's Award. *Radiology* 1990;174:1043. [PubMed: 2305087]
79. Shabsigh R, Fishman IJ, Schum C, et al. Cigarette smoking and other vascular risk factors in vasculogenic impotence. *Urology* 1991;38:227. [PubMed: 1887536]
80. Andersen KV, Bovim G. Impotence and nerve entrapment in long distance amateur cyclists. *Acta Neurol Scand* 1997;95:233. [PubMed: 9150814]
81. Ricchiuti VS, Haas CA, Seftel AD, et al. Pudendal nerve injury associated with avid bicycling. *J Urol* 1999;162:2099. [PubMed: 10569585]
82. Junemann KP, Aufenanger J, Konrad T, et al. The effect of impaired lipid metabolism on the smooth muscle cells of rabbits. *Urol Res* 1991;19:271. [PubMed: 1949424]
83. Rosen MP, Greenfield AJ, Walker TG, et al. Cigarette smoking: an independent risk factor for atherosclerosis in the hypogastric-cavernous arterial bed of men with arteriogenic impotence. *J Urol* 1991;145:759. [PubMed: 2005695]
84. Martin-Morales A, Sanchez-Cruz JJ, Saenz de Tejada I, et al. Prevalence and independent risk factors for erectile dysfunction in Spain: results of the Epidemiologia de la Disfuncion Erectil Masculina Study. *J Urol* 2001;166:569. [PubMed: 11458070]
85. Feldman HA, Goldstein I, Hatzichristou DG, et al. Impotence and its medical and psychosocial correlates: results of the Massachusetts Male Aging Study. *J Urol* 1994;151:54. [PubMed: 8254833]
86. Virag R, Bouilly P, Frydman D. Is impotence an arterial disorder? A study of arterial risk factors in 440 impotent men. *Lancet* 1985;1:181. [PubMed: 2857264]
87. Sullivan ME, Thompson CS, Dashwood MR, et al. Nitric oxide and penile erection: is erectile dysfunction another manifestation of vascular disease? *Cardiovasc Res* 1999;43:658. [PubMed: 10690337]
88. Tarhan F, Kuyumcuoglu U, Kolsuz A, et al. Cavernous oxygen tension in the patients with erectile dysfunction. *Int J Impot Res* 1997;9:149. [PubMed: 9315492]
89. Moreland RB, Traish A, McMillin MA, et al. PGE1 suppresses the induction of collagen synthesis by transforming growth factor-beta 1 in human corpus cavernosum smooth muscle. *J Urol* 1995;153:826. [PubMed: 7861547]
90. Nehra A, Gettman MT, Nugent M, et al. Transforming growth factor-beta1 (TGF-beta1) is sufficient to induce fibrosis of rabbit corpus cavernosum in vivo. *J Urol* 1999;162:910. [PubMed: 10458407]
91. Saenz de Tejada I, Moroukian P, Tessier J, et al. Trabecular smooth muscle modulates the capacitor function of the penis. Studies on a rabbit model. *Am J Physiol* 1991;260:H1590. [PubMed: 2035679]
92. Nehra A, Azadzi KM, Moreland RB, et al. Cavernosal expandability is an erectile tissue mechanical property which predicts trabecular histology in an animal model of vasculogenic erectile dysfunction. *J Urol* 1998;159:2229. [PubMed: 9598575]
93. Mulvany MJ. Small artery remodeling in hypertension. *Curr Hypertens Rep* 2002;4:49. [PubMed: 11790292]
94. Okabe H, Hale TM, Kumon H, et al. The penis is not protected--in hypertension there are vascular changes in the penis which are similar to those in other vascular beds. *Int J Impot Res* 1999;11:133. [PubMed: 10404281]
95. Toblli JE, Stella I, Inserra F, et al. Morphological changes in cavernous tissue in spontaneously hypertensive rats. *Am J Hypertens* 2000;13:686. [PubMed: 10912754]
96. Hale TM, Okabe H, Heaton JP, et al. Antihypertensive drugs induce structural remodeling of the penile vasculature. *J Urol* 2001;166:739. [PubMed: 11458127]
97. Norman RA Jr, Dzielak DJ. Immunological dysfunction and enhanced sympathetic activity contribute to the pathogenesis of spontaneous hypertension. *J Hypertens Suppl* 1986;4:S437. [PubMed: 3465908]

98. Mancia G, Grassi G, Giannattasio C, et al. Sympathetic activation in the pathogenesis of hypertension and progression of organ damage. *Hypertension* 1999;34:724. [PubMed: 10523349]
99. Panza JA, Quyyumi AA, Brush JE Jr, et al. Abnormal endothelium-dependent vascular relaxation in patients with essential hypertension. *N Engl J Med* 1990;323:22. [PubMed: 2355955]
100. Taddei S, Virdis A, Ghiadoni L, et al. Vitamin C improves endothelium-dependent vasodilation by restoring nitric oxide activity in essential hypertension. *Circulation* 1998;97:2222. [PubMed: 9631871]
101. Cai H, Harrison DG. Endothelial dysfunction in cardiovascular diseases: the role of oxidant stress. *Circ Res* 2000;87:840. [PubMed: 11073878]
102. Suwaidi JA, Hamasaki S, Higano ST, et al. Long-term follow-up of patients with mild coronary artery disease and endothelial dysfunction. *Circulation* 2000;101:948. [PubMed: 10704159]
103. Schachinger V, Britten MB, Zeiher AM. Prognostic impact of coronary vasodilator dysfunction on adverse long-term outcome of coronary heart disease. *Circulation* 2000;101:1899. [PubMed: 10779454]
104. Rizzoni D, Porteri E, Castellano M, et al. Endothelial dysfunction in hypertension is independent from the etiology and from vascular structure. *Hypertension* 1998;31:335. [PubMed: 9453325]
105. Rizzoni D, Porteri E, Castellano M, et al. Vascular hypertrophy and remodeling in secondary hypertension. *Hypertension* 1996;28:785. [PubMed: 8901824]
106. Konishi M, Su C. Role of endothelium in dilator responses of spontaneously hypertensive rat arteries. *Hypertension* 1983;5:881. [PubMed: 6654451]
107. Behr-Roussel D, Chamiot-Clerc P, Bernabe J, et al. Erectile dysfunction in spontaneously hypertensive rats: pathophysiological mechanisms. *Am J Physiol Regul Integr Comp Physiol* 2003;284:R682. [PubMed: 12611393]
108. Rajagopalan S, Kurz S, Munzel T, et al. Angiotensin II-mediated hypertension in the rat increases vascular superoxide production via membrane NADH/NADPH oxidase activation. Contribution to alterations of vasomotor tone. *J Clin Invest* 1996;97:1916. [PubMed: 8621776]
109. Heitzer T, Wenzel U, Hink U, et al. Increased NAD(P)H oxidase-mediated superoxide production in renovascular hypertension: evidence for an involvement of protein kinase C. *Kidney Int* 1999;55:252. [PubMed: 9893134]
110. Cosentino F, Patton S, d'Uscio LV, et al. Tetrahydrobiopterin alters superoxide and nitric oxide release in prehypertensive rats. *J Clin Invest* 1998;101:1530. [PubMed: 9525996]
111. Yang D, Feletou M, Boulanger CM, et al. Oxygen-derived free radicals mediate endothelium-dependent contractions to acetylcholine in aortas from spontaneously hypertensive rats. *Br J Pharmacol* 2002;136:104. [PubMed: 11976274]
112. Paniagua OA, Bryant MB, Panza JA. Transient hypertension directly impairs endothelium-dependent vasodilation of the human microvasculature. *Hypertension* 2000;36:941. [PubMed: 11116104]
113. Rajfer J, Rosciszewski A, Mehringer M. Prevalence of corporeal venous leakage in impotent men. *J Urol* 1988;140:69. [PubMed: 3379701]
114. Metz P, Ebbehøj J, Uhrenholdt A, et al. Peyronie's disease and erectile failure. *J Urol* 1983;130:1103. [PubMed: 6644889]
115. Iacono F, Barra S, de Rosa G, et al. Microstructural disorders of tunica albuginea in patients affected by impotence. *Eur Urol* 1994;26:233. [PubMed: 7805709]
116. Iacono F, Barra S, De Rosa G, et al. Microstructural disorders of tunica albuginea in patients affected by Peyronie's disease with or without erection dysfunction. *J Urol* 1993;150:1806. [PubMed: 8230510]
117. Dalkin BL, Carter MF. Venogenic impotence following dermal graft repair for Peyronie's disease. *J Urol* 1991;146:849. [PubMed: 1843616]
118. Christ GJ, Maayani S, Valcic M, et al. Pharmacological studies of human erectile tissue: characteristics of spontaneous contractions and alterations in alpha-adrenoceptor responsiveness with age and disease in isolated tissues. *Br J Pharmacol* 1990;101:375. [PubMed: 1701678]
119. Cerami A, Vlassara H, Brownlee M. Glucose and aging. *Sci Am* 1987;256:90. [PubMed: 3589642]

120. Hayashi K, Takamizawa K, Nakamura T, et al. Effects of elastase on the stiffness and elastic properties of arterial walls in cholesterol-fed rabbits. *Atherosclerosis* 1987;66:259. [PubMed: 3651177]
121. Sattar AA, Haot J, Schulman CC, et al. Comparison of anti-desmin and anti-actin staining for the computerized analysis of cavernous smooth muscle density. *Br J Urol* 1996;77:266. [PubMed: 8800897]
122. Mersdorf A, Goldsmith PC, Diederichs W, et al. Ultrastructural changes in impotent penile tissue: a comparison of 65 patients. *J Urol* 1991;145:749. [PubMed: 2005694]
123. Pickard RS, King P, Zar MA, et al. Corpus cavernosal relaxation in impotent men. *Br J Urol* 1994;74:485. [PubMed: 7820428]
124. Fan SF, Brink PR, Melman A, et al. An analysis of the Maxi-K+ (KCa) channel in cultured human corporal smooth muscle cells. *J Urol* 1995;153:818. [PubMed: 7861546]
125. Azadzo KM, Park K, Andry C, et al. Relationship between cavernosal ischemia and corporal veno-occlusive dysfunction in an animal model. *J Urol* 1997;157:1011. [PubMed: 9072535]
126. Christ GJ, Moreno AP, Parker ME, et al. Intercellular communication through gap junctions: a potential role in pharmacomechanical coupling and syncytial tissue contraction in vascular smooth muscle isolated from the human corpus cavernosum. *Life Sci* 1991;49:PL195. [PubMed: 1943478]
127. Lerner SE, Melman A, Christ GJ. A review of erectile dysfunction: new insights and more questions. *J Urol* 1993;149:1246. [PubMed: 8097541]
128. Persson C, Diederichs W, Lue TF, et al. Correlation of altered penile ultrastructure with clinical arterial evaluation. *J Urol* 1989;142:1462. [PubMed: 2685365]
129. Azadzo KM, Saenz de Tejada I. Hypercholesterolemia impairs endothelium-dependent relaxation of rabbit corpus cavernosum smooth muscle. *J Urol* 1991;146:238. [PubMed: 2056597]

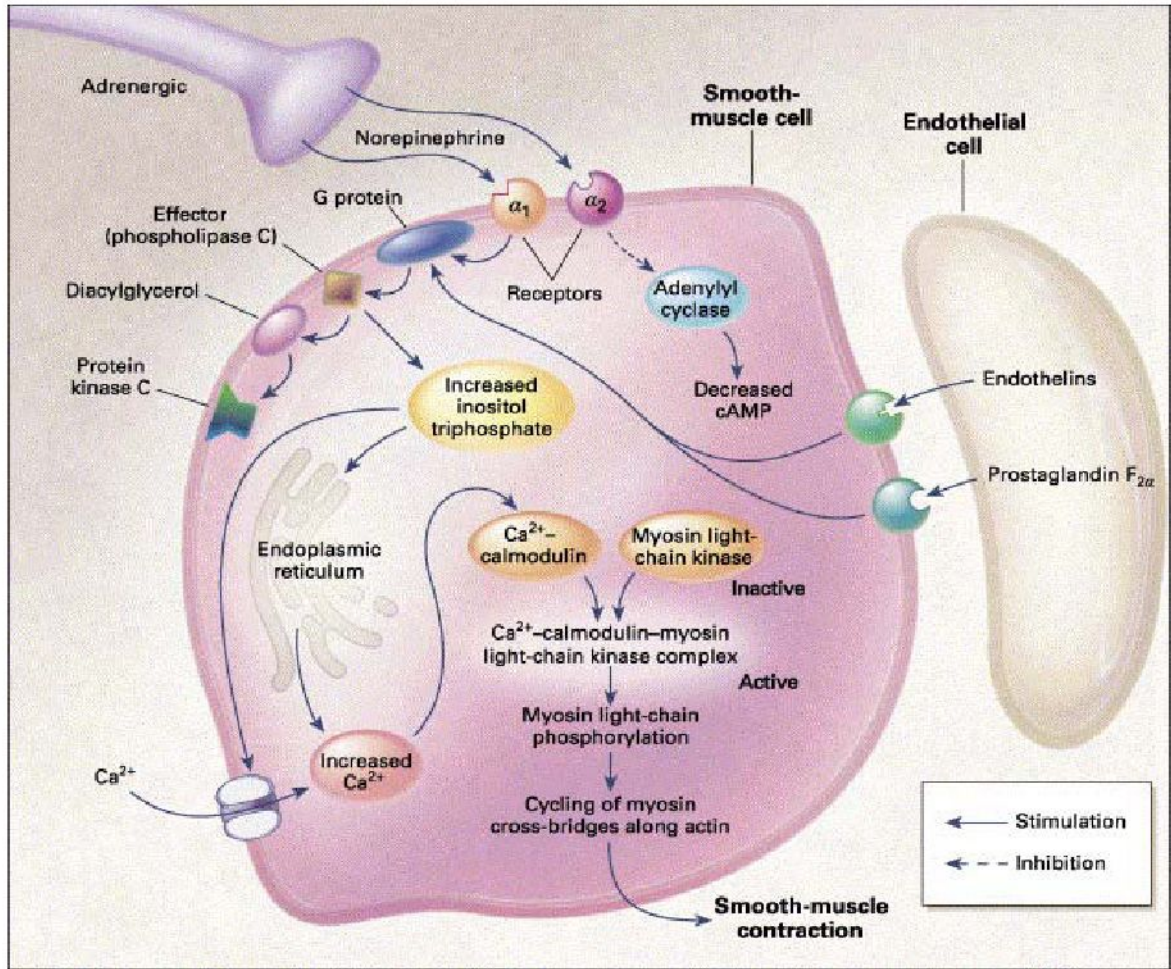


Figure 1. Molecular mechanism of penile smooth muscle contraction. Norepinephrine from sympathetic nerve endings and endothelins and PGF_{2α} from the endothelium activate receptors on smooth muscle cells to initiate the cascade of reactions that eventually result in elevation of intracellular calcium concentrations and smooth muscle contraction. Protein kinase C is a regulatory component of the Ca²⁺-independent, sustained phase of agonist-induced contractile responses. (From Lue TF: Erectile dysfunction. *N Engl J Med* 2000;342:1802–1813. Copyright “ 2000 Massachusetts Medical Society. All rights reserved.)

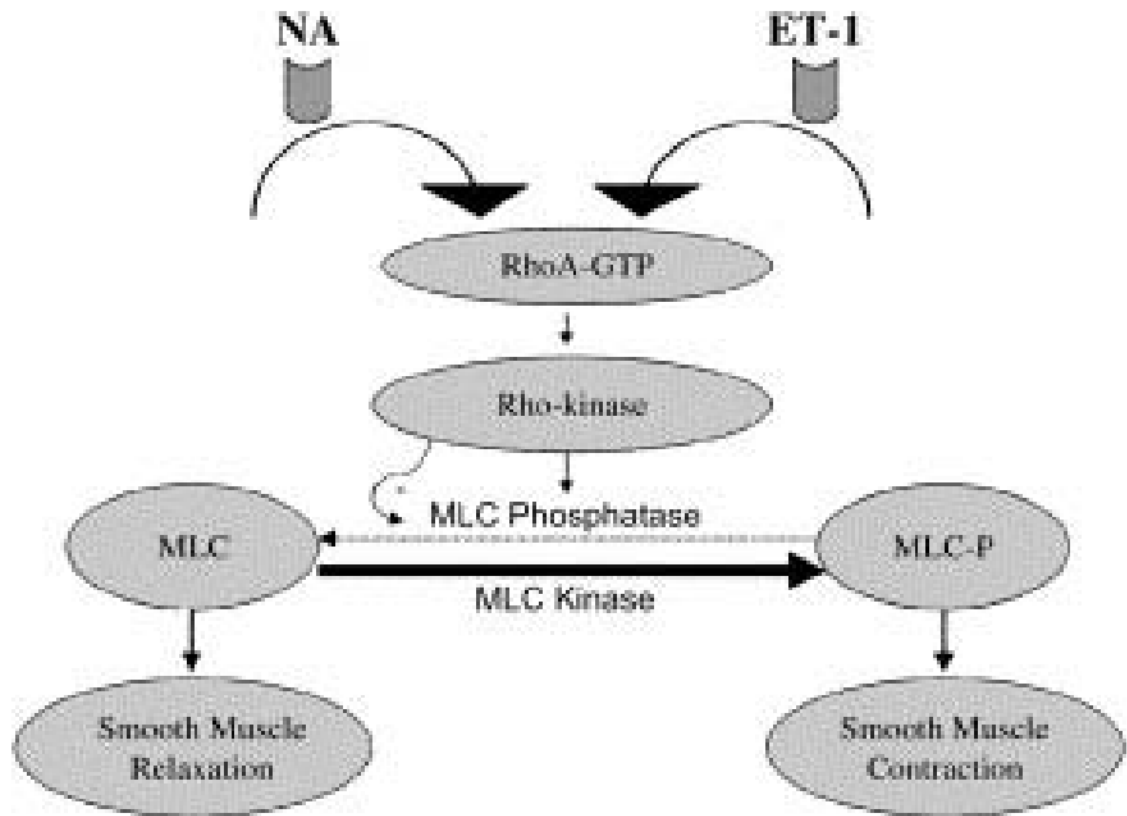


Figure 2. RhoA/Rho kinase pathway: the calcium sensitization pathway.

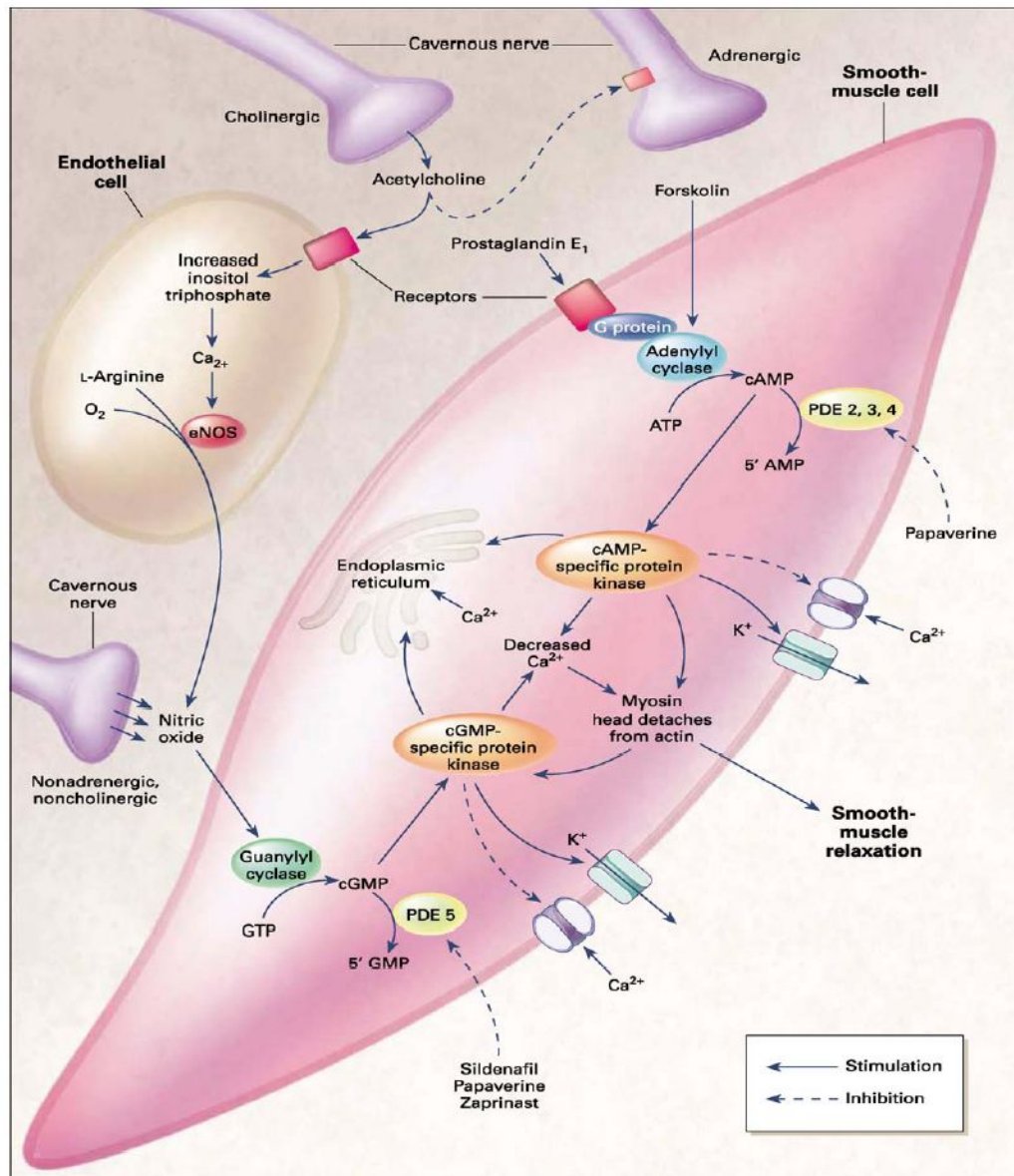


Figure 3. Molecular mechanism of penile smooth muscle relaxation. The intracellular second messengers mediating smooth muscle relaxation, cAMP and cGMP, activate their specific protein kinases, which phosphorylate certain proteins to cause opening of potassium channels, closing of calcium channels, and sequestration of intracellular calcium by the endoplasmic reticulum. The resultant fall in intracellular calcium leads to smooth muscle relaxation. Sildenafil inhibits the action of PDE5 and thus increases the intracellular concentration of cGMP. Papaverine is a nonspecific phosphodiesterase inhibitor. eNOS, endothelial nitric oxide synthase. (From Lue TF: Erectile dysfunction. *N Engl J Med* 2000;342:1802--1813. Copyright © 2000 Massachusetts Medical Society. All rights reserved.)

TABLE 1
Brain activation centers and corresponding function

Brain activation regions	Functional association
Bilateral inferior temporal cortex (right > left)	Visual association area
Right insula	Processes somatosensory information with motivational states
Right inferior frontal cortex	Processes sensory information
Left anterior cingulate cortex	Controls autonomic and neuroendocrine function
Right occipital gyrus	Visual processing
Right hypothalamus	Male copulatory behavior
Left caudate (the striatum)	Attentional processing and guide responsiveness to new environmental stimuli

TABLE 2
Classification of Male Erectile Dysfunction

Organic

- I.** Vasculogenic
 - A.** Arteriogenic
 - B.** Cavemosal
 - C.** Mixed
- II.** Neurogenic
- III.** Anatomic
- IV.** Endocrinologic

Psychogenic

- I.** Generalized
 - A.** Generalized unresponsiveness
 - 1.** Primary lack of sexual arousability
 - 2.** Aging-related decline in sexual arousability
 - B.** Generalized inhibition
 - 1.** Chronic disorder of sexual intimacy
 - II.** Situational
 - A.** Partner-related
 - 1.** Lack of arousability in specific relationship
 - 2.** Lack of arousability owing to sexual object preference
 - 3.** High central inhibition owing to partner conflict or threat
 - B.** Performance-related
 - 1.** Associated with other sexual dysfunction/s (e.g. rapid ejaculation)
 - 2.** Situational performance anxiety (e.g. fear of failure)
 - C.** Psychological distress- or adjustment-related
 - 1.** Associated with negative mood state (e.g. depression) or major life stress (e.g. death of partner)
-