

Septic deep venous thrombosis in intravenous drug users

Franz Füh, Werner Zimmerli, Marianne Jordi, Ronald A. Schoenenberger

Clinic of Internal Medicine, Bürgerspital, Solothurn, Switzerland

Summary

Objective: To review diagnostic and therapeutic experience in seven patients with septic deep vein thrombosis (DVT) after intravenous use of illicit drugs.

Methods: Retrospective review of medical records and prospective data collection in intravenous drug users (IVDU) who presented with a confirmed diagnosis of DVT and sepsis during a period of 18 months in a single institution.

Results: Of seven long-term IVDU (age 24–40 years), who had repeatedly attempted venous access to proximal veins, five had femoral DVT and one each jugular and brachial DVT. All DVT were confirmed by contrast-enhanced helical CT or ultrasonography. Median C-reactive protein (CRP) was 215 mg/l (range 76–386). Multiple blood cultures grew Gram-positive bacteria in 7 of 8 patients, chiefly *Staphylococcus aureus*, confirming an intravascular infection with continuous bacteraemia. Therapy consisted of intravenous β -lactamase-resistant penicillin until normalisation of CRP (3–4 weeks), initially combined with an

aminoglycoside for a few days. The mean defervescence time was 7.4 days (range 3–12). All patients were given intravenous heparin overlapping with oral anticoagulation without major side effects. Surgical exploration of the venous vasculature was never necessary. Mean hospital stay was 25.7 days (range 10–47).

Conclusion: Septic DVT in IVDU is a potentially life-threatening disorder that may become more frequent as the number of long-term IVDU increases. Helical CT or colour-coded Doppler ultrasound is the confirmatory imaging procedure of choice. Empirical antibiotic therapy should include a β -lactamase-resistant penicillin since *S. aureus* is the most common pathogen isolated. Anticoagulation can be safely initiated once the diagnosis of DVT is confirmed. Surgery is necessary only in rare instances of septic DVT.

Key words: deep venous thrombosis; sepsis; intravenous drug use; therapy

Introduction

Aseptic thrombophlebitis of peripheral veins due to intravenous catheters and catheter-related bacteraemia, which both usually respond to removal of the intravascular device, are common conditions [1]. Septic or suppurative thrombophlebitis of large proximal veins, a condition characterised by microabscess formation within the thrombotic vein and repeated bacterial embolisation into the circulation, is a severe systemic disease which has received little attention in the literature [2–4].

In intravenous drug users (IVDU), skin or subcutaneous abscesses and suppurative thrombophlebitis of small veins are well-recognised complications after unsterile and usually unsuc-

cessful attempts to gain access to peripheral veins [5–7]. After years of intravenous drug use, superficial and peripheral veins may become obliterated so that proximal and more central veins are used for drug injection. Besides mechanical and toxic complications (pneumothorax, intraarterial drug injection), the use of large proximal veins may result in life-threatening septic deep vein thrombosis [8, 9].

We recently observed seven IVDU with septic deep vein thrombosis within a period of 18 months. This report summarises our experience in the diagnosis, treatment and follow-up of these patients.

Methods

The charts of the first three patients with septic deep vein thrombosis were reviewed retrospectively while the next four patients were evaluated prospectively. All patients had sepsis, six with positive blood cultures [10]. Contrast-enhanced helical computed tomography (CT) and/or colour-coded Doppler ultrasonography were used to document deep vein thrombosis. Patients underwent routine laboratory studies, including complete blood

count, electrolyte determination, blood cultures and screening tests for hepatitis B and C and HIV infection. The length of stay, duration of fever, the type of microorganism, type and concentration of antimicrobial agent and complications were reviewed in detail. Follow-up was ascertained by cross-check with the hospital's computer patient log or telephone contact with the patient's family physician.

Results

Clinical data and evolution of the seven patients with septic deep vein thrombosis are summarised in table 1. All patients had a history of intravenous drug use lasting 8–16 years. Five patients had venous thrombosis of the femoral and iliac veins and one each of the internal jugular vein and the deep veins of the upper arm. All infective agents were Gram-positive bacteria. In six of seven patients multiple blood cultures were positive. In two patients all blood cultures were positive for two different species. At the initial presentation all the patients fulfilled the criteria for sepsis [10]. The history of drug injection into proximal veins of the extremities and the local clinical findings (pain, swelling, warmth) already suggested an injection-related infectious complication in five patients from the outset. In one patient who attempted access to the jugular veins, impaired consciousness and severe headache led to the initial diagnosis of meningitis, which was then ruled out. In another patient multiple pulmonary abscesses led to the initial diagnosis of probable right-heart endocarditis, which was then ruled out by transoesophageal echocardiography and a positive finding of deep vein thrombosis of the leg.

Contrast-enhanced helical CT was used in five out of seven patients and colour-coded duplex ultrasonography in two as confirmatory imaging procedures for deep vein thrombosis. Five out of six patients with *S. aureus* infection were treated with a β -lactamase-resistant penicillin (flucloxacillin) by the iv route for at least 14 days, usually in combination with an aminoglycoside for one week. In three of these five patients flucloxacillin was given for 3–4 weeks, in one patient it was replaced by intravenous co-amoxiclav for 2 weeks, and in another patient oral ciprofloxacin was given for the second two weeks. One patient with *S. aureus* disease was treated with iv co-amoxiclav for only 10 days due to his departure from hospital without notice.

All patients were started on intravenous heparin as soon as deep vein thrombosis was diagnosed, then switched to oral anticoagulation (target INR 2–3) for the duration of the hospital stay. Five patients were maintained on oral anticoagulation for at least three months after discharge.

The mean time to defervescence was 7.4 days (range 3–12). The mean length of hospital stay was 25.7 days (range 10–47).

Case reports

In the following we describe the case histories of three patients in greater detail.

Case 1 (patient K.A.: table 1)

A 30-year-old white male was admitted for inpatient evaluation with high grade fever and severe right-sided headache. He had a history of poorly controlled type 1 diabetes mellitus and of on-and-off intravenous drug use for more than ten years. He had entered a methadone substitution programme (60 mg/day) nine months previously but had continued occasional iv use of heroin and cocaine. On admission the patient appeared malnourished and severely ill. Temperature 38.9°C, heart rate 124/min, respiration rate 18/min, blood pressure 105/80 mm Hg. There were multiple excoriated, crusted lesions on both forearms, groins and bilaterally on the neck where he had repeatedly attempted venous access to the brachial, femoral and jugular veins. There was marked tenderness on palpation as well as soft tissue swelling of the right anterolateral cervical region. Neither regional lymphadenopathy nor nuchal rigidity was noted.

Admission laboratory tests revealed the following abnormal results (normal values in parenthesis): C-reactive protein (CRP) 194 mg/l (<5), haemoglobin 12.2 gr% (14–18), white cell count 10.4×10^9 (3–10) with 72.5% band forms, platelet count 113×10^9 /l (125–400), D-dimer 860 μ g/l (<230), sodium 127 mmol/l (133–145), calcium 2.14 mmol/l (2.16–2.60), alkaline phosphatase 203 U/l (31–108), γ -glutamyltransferase 114 U/l (1–64), and serum albumin 26 gr/l (40–50). Haemoglobin A1c was 16.6% (2.9–7.1). HIV screening was negative. In 4 of 4 blood cultures *Staphylococcus epidermidis* and *Arcanobacterium haemolyticus* grew 24 hours after admission.

A lumbar tap revealed normal cerebrospinal fluid. The patient was started on intravenous flucloxacillin 2 gr and netilmicin 100 mg, both every eight hours. Contrast enhanced helical CT scan of the neck and chest showed thrombotic occlusion of both internal jugular veins (fig. 1). There was an air inclusion in the left-sided thrombus. A suspicion of thrombus extension into the right subclavian vein and the right sinus cavernosus was

Table 1
Synopsis of seven patients with septic thrombosis after drug injection into large proximal veins. CRP: C-reactive protein; WBC: white blood cell count.

Patient, age, sex	Thrombosis	Microorganism	Material with bacterial growth	Concomitant disease	CRP (mg/l) WBC (10 ⁹ /l) % band forms	Diagnostic Imaging	Therapy	Time to defervescence (days)*	Length of hospital stay (days)	Follow-up
K.A., 30, m	V. jugularis interna bil	<i>Staphylococcus epidermidis</i> <i>Aerobacterium haemolyticus</i>	Blood cultures (4/4)	Diabetes mellitus 1 Hepatitis B	194 10.2 72.5	CT Duplex sonography	Flucloxacillin 2 gr iv q 8 h × 21 days + netilmicin 100 mg iv q 8 h × 10 days, then co-amoxiclav 1.2 gr iv q 8 h × 10 days, followed by co-amoxiclav 62.5 mg tid × 10 days	3	47	Drug free after 12 months Still on oral anticoagulation
W.K., 24, f	V. femoralis communis sin	<i>Staphylococcus aureus</i> Group C streptococcus	Blood cultures (4/4) and inguinal wound (both agents)	Hepatitis C	142 9.7 32	Duplex sonography	Flucloxacillin 2 gr iv q 6 h × 14 days + netilmicin 150 mg q 12 h × 14 days, then ciprofloxacin 750 mg po bid × 14 days	10	16	Readmission after 8 months for contra- lateral inguinal abscess
T.G., 40, f	V. femoralis communis and V. iliaca externa sin	<i>Staphylococcus aureus</i>	Blood cultures (8/8) and inguinal wound	Hepatitis B and C	230 13.4 21	CT	Flucloxacillin 2 gr iv q 6 h × 28 days + amikacin 750 mg iv q 24 h × 7 days + clindamycin 500 mg iv q 18 h × 5 days	11	36	Persistent painful leg swelling after 6 months readmission for inguinal abscess dx
K.N., 26, f	V. femoralis superficialis sin V. iliaca externa sin	<i>Staphylococcus aureus</i> (Blood cultures negative)	Inguinal wound	none	76 9.3 23	CT Duplex sonography	Co-amoxiclav 1.2 gr iv q 8 × 10 days	6	10	Readmission after 7 months for ipsilateral inguinal abscess
H.O., 30, m	V. mediana cubiti sin and V. basilica sin	<i>Staphylococcus aureus</i>	Blood cultures (6/6)	Hepatitis B and C HIV-infection AI	215 10.7 18	Duplex sonography	Co-amoxiclav 1.2 gr iv q 8 h × 3 days, then flucloxacillin 2 gr q 6 h × 20 days	5	14	Readmission for dental abscess after 14 months. Progression of HIV disease
B.T., 26, f	V. femoralis superficialis and V. femoralis communis dx	Group A streptococcus	Blood cultures (6/6)	none	386 19.1 51.5	CT	Flucloxacillin 2 gr iv q 8 h × 4 days + amikacin 750 mg iv q 24 h × 4 days, followed by penicillin G 5 Mio. E q 6 h × 25 days	12	30	Readmission after 2 months for septic gonarthritis (Group A streptococcus)
A.M., 34, m	V. femoralis superficialis and V. femoralis communis dx	<i>Staphylococcus aureus</i>	Blood cultures (4/4) and sputum	none	255 17.5 45.5	CT	Flucloxacillin 2 gr iv q 6 h × 21 days + amikacin 500 mg iv q 24 h × 4 days, followed by ciprofloxacin 750 mg po bid × 7 days	5	27	Drug free and no readmission for 3 months

* defined as body temperature <37° for ≥24 hours

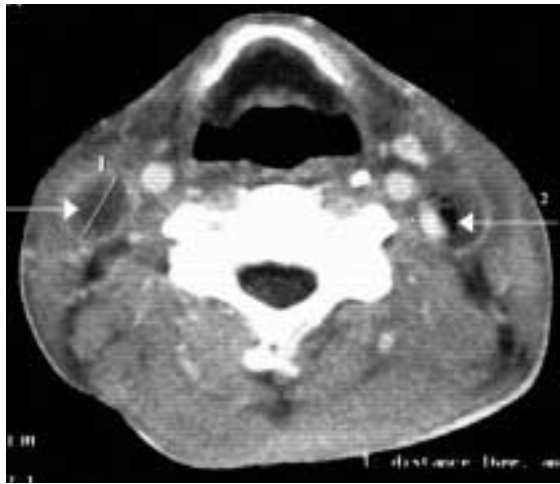

Figure 1

Contrast enhanced helical CT of the neck at the level of the hyoid revealing thrombotic occlusion of both internal jugular veins (arrows) with air inclusion on the left side (arrow 2).

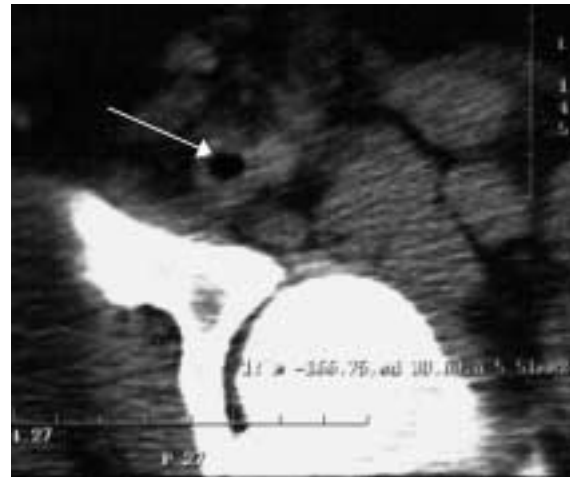


Figure 2

Contrast enhanced helical CT image (detail) of the left inguinal region at the level of ramus superior ossis pubis showing thrombosis of the left iliac vein with air inclusion (arrow) and soft tissue oedema.

noted. The patient was put on intravenous heparin and oral anticoagulation with acenocoumarol was started.

72 hours later the patient's fever subsided. The facial and neck swelling, however, persisted. A CT scan of the neck was repeated and showed a perijugular fluid collection along the right V. jugularis interna. Colour-Doppler sonography of the neck veins confirmed the diagnosis of thrombotic occlusion of both internal jugular veins. Consultant surgeons rejected operation and recommended conservative treatment. The facial and neck swelling gradually improved. After 3 weeks antibiotic treatment was switched to co-amoxiclav (1.2 g iv tid) and continued for another two weeks. The CRP decreased from initially 194 mg/l to 28 mg/l after 5 days, stayed at levels between 25 and 35 mg/l for 3 weeks and then normalised to 8 mg/l before discharge. The patient was discharged on insulin and oral anticoagulation for 3 months to an institution specialising in addiction therapy, where he made an uneventful recovery.

Case 2 (patient T.G.: table 1)

A 30-year-old white woman was admitted to hospital by her family physician for general malaise, fever of unknown origin and a swollen left lower limb. Because of the patient's 12-year history of intravenous drug use and a loud systolic murmur, the admitting physician suspected acute infective endocarditis. The patient was on oral methadone maintenance therapy (100 mg/d), but continued to use iv heroin, cocaine and methadone regularly. For more than two years she had regularly attempted venous access in both groins. Two years previously she had had deep venous thrombosis of the right leg and had been anticoagulated. This therapy was halted one week prior to admission because of major blood loss from a self-inflicted, accidental puncture of the left femoral artery.

On admission the patient was weak and obtunded. She complained of severe generalised myalgia and arthralgia. Temperature 38.8°C, heart rate 82/min, blood pressure 120/60 mm Hg. There were multiple injection marks in both inguinal regions. In the left groin there was a small skin fistula with a minor but continuously oozing haemorrhage. The entire left lower limb showed painful swelling, livid discolouration and increased skin temperature. Cardiac auscultation revealed a grade 4 systolic murmur. Rales were audible over the left lung.

Admission laboratory tests revealed the following abnormal results (normal values in parenthesis): CRP 230

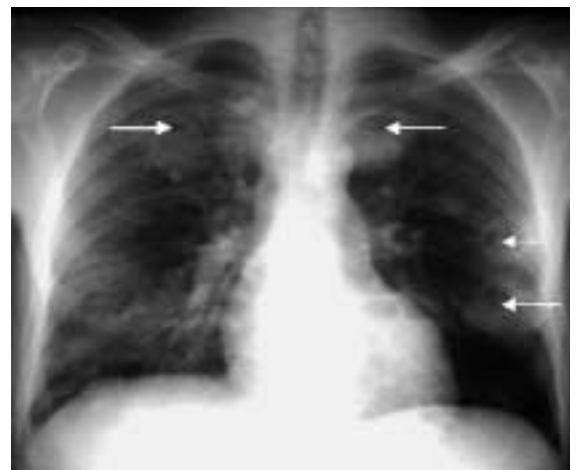

Figure 3

Chest radiography with multiple abscesses and air-fluid levels (arrows) of both lungs due to pulmonary emboli.

mg/l (<5), haemoglobin 9.2 gr% (14-16), MCV 74 fl (80-102), MCH 23 pg (27-33), white cell blood count 13.4×10^9 (3-10) with 21% band forms, D-dimer 791 $\mu\text{g/l}$ (<230), creatinine 182 $\mu\text{mol/l}$ (45-110), urea 11.0 mmol/l (1.7-8.3), and aspartate aminotransferase 46 U/l (11-41). HIV screening was negative.

Contrast-enhanced helical CT scan of the pelvis and the proximal lower limbs showed extensive thrombosis of the left iliac, femoral and popliteal veins (fig. 2). Air inclusions were visible in the thrombotic veins. Significant soft-tissue oedema and enlarged inflamed inguinal lymph nodes were present. The patient was given intravenous fluids and was put on intravenous heparin (1000 IU/h). 24 hours later *Staphylococcus aureus* grew in 8 of 8 blood cultures. The patient was started on flucloxacillin 2 gr iv q 6 h, clindamycin 500 mg iv q 8 h, and amikacin 750 mg iv q 24 h. A consultant in vascular surgery recommended conservative treatment. Three days after admission the temperature spiked to 39.2°C and the patient complained of a sharp right-sided chest pain. Chest x-ray showed an infiltrate suggestive of septic pulmonary embolism. However, transoesophageal echocardiography showed normal left ventricular function and no vegetation, valvular regurgitation or other signs of endocarditis. Clindamycin

was stopped after 7 days and amikacin after 10 days. The temperature gradually returned to normal within 14 days and the painful swelling of the left leg improved. The patient was put on oral anticoagulation. Flucloxacillin was given for four weeks in an unchanged dosage. The CRP normalised after three weeks and stayed normal one week after the antibiotic therapy was stopped. The patient was discharged on phenprocoumon, methadone and with compression stockings.

Case 3 (patient A.M.: table 1)

A 34-year old white male referred himself for general malaise with fever for more than one week. He had used illicit intravenous drugs for more than ten years. After a short period of abstinence he had resumed heroin and cocaine use five months before admission. He regularly used the right femoral vein for venous access. On admission the patient appeared severely ill and malnourished. Temperature 39.6°C, heart rate 108/min., blood pressure 115/60 mm Hg. There were multiple injection marks in the right inguinal region. During physical examination he repeatedly exhibited a heavy cough and produced malodorous, purulent sputum. Lung auscultation revealed diminished breath sounds with inspiratory rales on both sides. A grade 3 systolic murmur was noted on cardiac auscultation. The liver was slightly enlarged and tender on palpation. There was no swelling, discolouration or pain of the lower extremities indicative of deep vein thrombosis.

Admission laboratory tests showed the following abnormal results (normal values in parenthesis): CRP 255 mg/l (<5), haemoglobin 9.8 gr% (14–18), white cell count $17.5 \times 10^9/l$ (3–10) with 45.5% band forms, platelet count

$671 \times 10^9/l$ (125–400), D-dimer 958 µg/l (<230), aspartate aminotransferase 45 U/l (–41), and alkaline phosphatase 149 U/l (31–108). HIV screening was negative.

Chest radiography revealed multiple bilateral circular lesions with air-fluid levels compatible with lung abscesses (fig. 3). Right heart endocarditis was suspected and intravenous antibiotic therapy with flucloxacillin 4 gr q 6 h and amikacin 500 mg q 24 h was begun. Four of four blood cultures returned positive for oxacillin-sensitive *Staphylococcus aureus* 24 hours after admission. Transoesophageal echocardiography showed a normal ejection fraction and no valvular dysfunction or vegetations. Two days after admission, a thoraco-abdominal contrast enhanced helical CT scan including both thighs revealed multiple lung abscesses, hepatosplenomegaly and extensive deep venous thrombosis of the right femoral veins. Septic deep venous thrombosis with septic pulmonary emboli was assumed.

Amikacin was withdrawn after four days and flucloxacillin continued for 21 days. Antibiotic therapy was first switched to oral co-amoxiclav which resulted in a rash after 24 hours. Oral ciprofloxacin 750 mg q 12 h was given for one more week. The patient was put on intravenous heparin three days after admission and switched to oral phenprocoumon (INR goal of 2–3) after one week. Recovery was uneventful: the temperature normalised and a second chest x-ray after two weeks showed clear regression of the bilateral abscesses. The patient was discharged on phenprocoumon for three months and oral methadone maintenance therapy to an institution specialised in the treatment of drug addiction.

Discussion

As superficial arm and leg veins become inaccessible with time, IVDU start to use more proximal and deeper veins. This practice may lead to severe non-infectious and infectious local complications, including soft-tissue abscesses, pneumothorax, haematoma and haemorrhage, traumatic arteriovenous fistula, thrombosis or mycotic aneurysms [5–7, 9]. We have recently observed seven IVDU with another distinct condition, namely septic deep vein thrombosis resulting from drug injection into proximal veins. All patients were severely ill at presentation. A history of attempts at drug injection into the femoral or jugular veins, local signs of thrombosis such as swelling and pain, and laboratory results pointing to a systemic bacterial infection made the diagnosis of septic thrombosis probable in most of our patients.

The diagnosis of deep vein thrombosis was confirmed either by contrast-enhanced helical CT or Doppler ultrasonography [11]. In our institution helical CT with a defined contrast infusion technique proved to be accurate if septic thrombosis was suspected [12, 13]. In contrast to ultrasound, CT can more readily visualise anatomical structures located in the pelvis, the dorsal cervical region, the base of the skull or the chest cavity. CT may therefore be more useful in demonstrating the full extent of thrombotic occlusion of proximal veins. Furthermore, CT may delineate pathologies

of the structures adjacent to the vein such as perivenous fluid, soft tissue abscesses or the extent of a concomitant haematoma. Ultrasound techniques are inexpensive, non-invasive and non-ionising, and have been shown to be accurate in the diagnosis of septic deep venous thrombosis as well, especially in patients with renal failure or contrast medium-associated allergic reactions [12].

As described in other reports, *S. aureus* was the predominant infective agent [3, 14, 15]. In two patients, two different Gram-positive bacteria were found. Gram-negative bacilli or fungi, which are more prevalent in patients with nosocomial, catheter-related suppurative thrombophlebitis, were not found in our patients [1, 16].

Initial empiric antibiotic therapy should include a β -lactamase-resistant penicillin such as flucloxacillin or amoxicillin/clavulanic acid by iv route. There are no data available on whether an aminoglycoside should be added. In four of our patients with *S. aureus* sepsis we added an aminoglycoside to the initial regimen for a couple of days, as recommended for patients with acute infective endocarditis [17, 18]. There are few empirical data on the optimal duration of antibiotic therapy and when therapy can safely be switched from intravenous to oral therapy. In a report on seven cases of septic thrombosis, intravenous antibiotic therapy lasted from 11–36 days depending on the clin-

ical evolution, serological infection markers and drug side effects [3]. By analogy with recommendations in patients with infective endocarditis, iv treatment should last at least four weeks. In patients with *S. aureus* thrombophlebitis, in whom prolonged iv treatment is not feasible, ciprofloxacin plus rifampicin may be a valuable alternative [19].

The value of early intravenous heparin followed by oral anticoagulation in patients with septic thrombosis, in which the femoral veins are usually involved, remains controversial. The presumed dangers include provocation of septic emboli from the infected thrombus itself or from a concomitant infective endocarditis, and even haemorrhagic complications from unrecognized mycotic arterial aneurysms. Indeed, patients with septic thrombosis belong to a population at particularly high risk for development of infective endocarditis, and some authors have stated that heparin therapy should be instituted only after infective endocarditis has been ruled out. In five of our seven patients echocardiography was performed and showed no signs of endocarditis. One patient probably had septic pulmonary embolism without compromising haemodynamics two days after initiating therapeutic intravenous heparin. Anticoagulation was unassociated with side effects in all the other patients, including the one who initially presented with multiple pulmonary septic emboli (patient A.M.: table 1). Given this experience, we believe that the risks of short-term anticoagulation are probably outweighed by the risk of major pulmonary emboli.

Surgery was never required in our series to control septic deep vein thrombosis. For superficial suppurative thrombophlebitis surgical excision has been recommended as an integral part of

treatment [20]. Resection of the involved vasculature in patients with septic thrombosis of larger proximal or central veins is either technically difficult or even impossible [15]. In patients with catheter-related septic deep vein thrombosis, resection or ligation of the involved veins or thrombectomy with removal of the infected clots has been reported to be helpful after unsuccessful conservative therapy [15]. In IVDU with septic thrombosis surgical therapy is only rarely necessary [21]. Our experience supports the view that medical therapy alone is usually sufficient [3, 14]. For concomitant problems such as soft tissue abscesses or septic arthritis, surgery may still be necessary.

In summary, septic deep vein thrombosis in IVDU is a potentially life-threatening disorder which may become more frequent as the number of long-term IVDU increases. Case history and clinical examination prompt suspicion of the correct diagnosis. Helical CT or colour-coded ultrasound are the confirmatory imaging procedures of choice. Blood cultures are mandatory in every IVDU presenting with deep vein thrombosis and fever. Empiric antibiotic therapy should be efficacious against *S. aureus*, which is the most common pathogen.

We thank Prof. Dr. med. P. Probst for helpful discussions of the CT-imaging results.

Correspondence:

Dr. med. F. Fäb

Medizinische Klinik

Bürgerspital

CH-4500 Solothurn

E-Mail: ffaeb_so@spital.ktso.ch

References

- Rupp ME. Infections of intravascular catheters and vascular devices. In: Crossley KB, Archer GL, eds. *The Staphylococci in Human Disease*. New York: Churchill Livingstone; 1997;379-399.
- Garrison RN, Richardson JD, Fry DE. Catheter-associated septic thrombophlebitis. *South Med J* 1982;75:917-919.
- Ang AK, Brown OW. Septic deep vein thrombosis. *J Vasc Surg* 1986;4:563-6.
- Andes DR, Urban UW, Acher CW, Maki DG. Septic thrombosis of the basilic, axillary, and subclavian veins caused by a peripherally inserted central venous catheter. *Am J Med* 1998;105:446-50.
- Scheidegger C, Zimmerli W. Infectious complications in drug addicts: seven-year review of 269 hospitalized narcotics abusers in Switzerland. *Rev Infect Dis* 1989;11:486-93.
- Scheidegger C, Zimmerli W. Incidence and spectrum of severe medical complications among hospitalized HIV-seronegative and HIV-seropositive narcotic drug users. *AIDS* 1996;10:1407-14.
- Binswanger IA, Kral AH, Bluthenthal RN, Rybold DJ, Edlin BR. High prevalence of abscesses and cellulitis among community-recruited injection drug users in San Francisco. *Clin Infect Dis* 2000;30:579-81.
- Weinberg G, Pasternak BM. Upper extremity suppurative thrombophlebitis and septic pulmonary emboli. *JAMA* 1978;240:1519.
- Bayer AS, Scheld WM. Suppurative thrombophlebitis. In: Mandell GL, Bennett JE, Dolin R, eds. *Mandell, Douglas, and Bennett's Principles and Practice of Infectious Diseases*, 5. ed. Philadelphia: Churchill Livingstone; 2000;884-888.
- Bone RC, Balk RA, Cerra FB, Dellinger RP, Fein AM, Knaus WA, et al. Definitions for sepsis and organ failure and guidelines for the use of innovative therapies in sepsis. The ACCP/SCCM Consensus Conference Committee. American College of Chest Physicians/Society of Critical Care Medicine. *Chest* 1992;101:1644-55.
- Cohen Y, Tit A, Brauner M, Fosse JP, Hoang P. Contribution of computerized tomography to the diagnosis of catheter-induced septic central venous thrombosis. *Intensive Care Med* 1996 Nov;22(11):1279-80.
- Albertyn LE, Alcock MK. Diagnosis of internal jugular vein thrombosis. *Radiology* 1987;161:505-8.
- Mori H, Fukada T, Isomoto I, Maeden H, Hayashi K. CT diagnosis of catheter-induced septic thrombus of vena cava. *J Comput Assist Tomogr* 1990;14:236-8.
- Vergheze A, Widrich WC, Arbeit RD. Central venous septic thrombophlebitis - the role of medical therapy. *Medicine* 1985;64:394-400.
- Niemeyer HW, Grabitz K, Buhl R, Wüst HJ, Sandmann W. Surgical treatment of septic deep venous thrombosis. *Surgery* 1995;118:49-53.

- 16 Tovi F. Septic thrombophlebitis of the internal jugular vein. *Isr J Med Sci* 1992;28:250–253.
- 17 Blatter M, Frei R, Zimmerli W. Therapie der infektiösen Endokarditis. *Schweiz Rundschau Med (PRAXIS)* 1994;83:1324–1331.
- 18 Wilson WR, Karchmer AW, Dajani AS, Taubert KA, Bayer A, Kaye D, et al. Antibiotic treatment of adults with infective endocarditis due to streptococci, staphylococci and HACEK microorganisms. *JAMA* 1995;274:1706–1713.
- 19 Dworkin RJ, Sande MA, Lee BL, Chambers HF. Treatment of right-sided *Staphylococcus aureus* endocarditis in intravenous drug users with ciprofloxacin and rifampicin. *Lancet* 1989; 1071–3.
- 20 Stein JM, Pruitt BA. Suppurative thrombophlebitis. A lethal iatrogenic disease. *N Engl J Med* 1970;282:1452–5.
- 21 Munster AM. Septic thrombophlebitis. A surgical disorder. *JAMA* 1974;230:1010–11.