



Temperate pyomyositis in an injecting drug misuser. A difficult diagnosis in a difficult patient

M Crossley

Emerg. Med. J. 2003;20;299-300
doi:10.1136/emj.20.3.299

Updated information and services can be found at:
<http://emj.bmjournals.com/cgi/content/full/20/3/299>

These include:

References

This article cites 6 articles, 1 of which can be accessed free at:
<http://emj.bmjournals.com/cgi/content/full/20/3/299#BIBL>

1 online articles that cite this article can be accessed at:
<http://emj.bmjournals.com/cgi/content/full/20/3/299#otherarticles>

Rapid responses

You can respond to this article at:
<http://emj.bmjournals.com/cgi/eletter-submit/20/3/299>

Email alerting service

Receive free email alerts when new articles cite this article - sign up in the box at the top right corner of the article

Topic collections

Articles on similar topics can be found in the following collections

[Other accident and emergency medicine](#) (1364 articles)
[Drug misuse](#) (328 articles)

Notes

To order reprints of this article go to:
<http://www.bmjournals.com/cgi/reprintform>

To subscribe to *Emergency Medicine Journal* go to:
<http://www.bmjournals.com/subscriptions/>

CASE REPORTS

The point of the needle. Occult pneumothorax: a review

P Gilligan, D Hegarty, T B Hassan

Emerg Med J 2003;**20**:293–296

The case of a patient with an unusual medical condition and an occult pneumothorax is presented. The evidence for management of occult pneumothorax particularly in patients with underlying lung disease is reviewed and solutions to the acute clinical problems that may arise are suggested.

A 27 year old man with histiocytosis X presented to the emergency department with left posterior chest wall pain and marked dyspnoea. The patient previously had recurrent pneumothoraces, eight on the right and two on the left. He had undergone pleurodesis of the right lung. His medical history also included invasive bronchopulmonary aspergillosis and an embolisation of the right pulmonary vessels for life threatening massive hemoptysis. He was on two litres per minute of home oxygen, which usually maintained his oxygen saturations around 94%.

On examination he was pale and sweaty with a heart rate of 160 per minute and a respiratory rate of 42 per minute. He had an oxygen saturation of 88% on 15 litres per minute of oxygen and a blood pressure of 76/45 mm Hg. Respiratory examination revealed diminished air entry bilaterally more marked on the left with increased resonance over the anterolateral left hemithorax. His trachea was noted to be central.

Emergency chest radiography was performed but while awaiting the return of the film the patient decompensated further, his saturations decreased to 81%, and his trachea was now deviated to the right. An emergency needle decompression of his left hemithorax was performed. In the context of his complicated medical history and the clinical findings the needle was inserted at the point of poorest air entry and

maximal resonance, which was the left sixth intercostal space in the anterior axillary line. Some 300 ml of air was aspirated from the left hemithorax and the patient clinically improved. The chest radiograph revealed bilateral infiltrates and underlying cystic and bullous disease but failed to reveal evidence of a pneumothorax (fig 1). A chest radiograph performed after the needle decompression also failed to show a pneumothorax. Computed tomography (CT) of the thorax revealed an anterior pneumothorax (fig 2). This was drained under CT guidance by the placement of a chest drain catheter.

During the patient's in hospital stay his chest drain was removed as his chest radiograph showed no evidence of residual pneumothorax. The patient became markedly dyspnoeic within 24 hours. Because of the clinical impression of the recurrence of the tension pneumothorax the patient had a needle decompression performed in the classic manner. The needle placed initially at the second intercostal space in the left midclavicular line failed to permit aspiration of air. An attempted needle decompression at the fourth intercostal space in the mid-axillary line was also unsuccessful. Urgent CT again confirmed a left sided anterior pneumothorax. A chest drain catheter was placed under CT guidance. The patient was discharged from hospital 23 days later. Resolution of the pneumothorax was confirmed by CT before discharge.

THE PROBLEM

Diagnosing a pneumothorax in patients with chronic lung disease may be difficult. Chest radiography may fail to show a pneumothorax—that is, an occult pneumothorax. How is occult pneumothorax best diagnosed and treated?

THE EVIDENCE

A search of the literature was undertaken using occult pneumothorax and its associations—that is, "OCCULT".mp.OR "VENTRAL".mp. OR "SUPINE".mp. OR "LOCALISED".mp. OR "LOCALIZED".mp. OR "DIFFICULT"..mp. OR "HIDDEN".mp. AND PNEUMOTHORAX/ or "PNEUMOTHORAX".mp.and "TENSION".mp. The limits to human and english language were applied. The search was performed using:

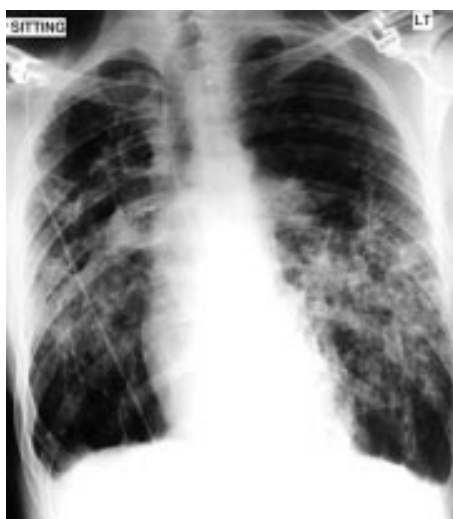

Figure 1 Chest radiograph consistent with underlying histiocytosis X but no obvious pneumothorax.

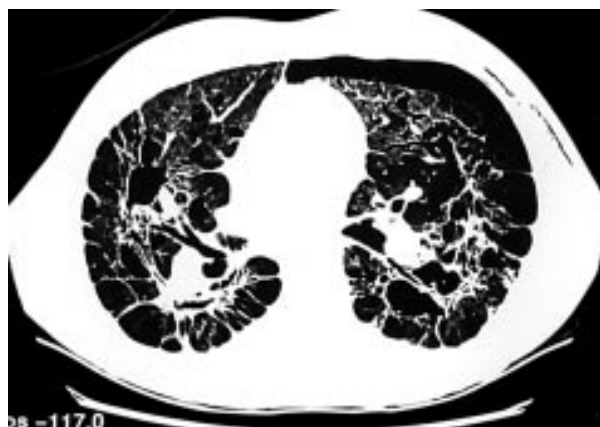

Figure 2 CT scan showing an anterior pneumothorax.

Key points

- Chest radiography remains the first approach to the diagnosis of pneumothorax, but it may fail to show the presence of all pneumothoraces, particularly where there is underlying lung disease.
- Tension pneumothorax is a clinical diagnosis requiring emergency needle decompression but this may be unsuccessful in loculated pneumothoraces.
- CT is the gold standard for the diagnosis of occult pneumothorax. It is extremely useful with regard to management decisions and can help in the performance and the assessment of the efficacy of interventions.

Medline from 1966 to December 2000; Best evidence 1991 to the present; The Cochrane Database of systematic reviews, issue 3, 2000; Cinahl 1982 to October 2000; Database of abstracts of Reviews of effectiveness 3rd quarter 2000; the medicine database; a search of the relevant bibliographies.

The relevant articles are included.

In most patients pneumothorax is readily detected.¹ Radiological confirmation of the diagnosis is based on the ability to observe the lucent band of air between the visceral and parietal pleura and recognising the opaque pleural stripe on the chest radiograph.² The association between Langerhan's histiocytosis X and pneumothoraces is well publicised, with the occurrence of pneumothorax in these patients being about 25%.³⁻⁷ In patients with cystic lung disease, the diagnosis of pneumothorax based on plain chest radiography alone may be difficult. Phillips *et al* noted that the complex appearance of the lungs themselves or partial adherence of the lung to the chest wall because of surgery or inflammation, or both of these factors, may result in an unusual configuration of the pneumothorax or mask it altogether.⁶

Occult pneumothorax has been defined as pneumothoraces seen on CT scans but not on routine chest radiographs.⁸⁻¹¹ Missed pneumothorax, which is a separate entity, may be defined as a pneumothorax that was seen on retrospective review of the chest radiograph but was small or subtle enough not to be diagnosed prospectively.¹² The phenomenon of occult pneumothorax is well described in the trauma literature with an incidence of between 2% and 12%.⁸ Hehir *et al* postulated that part of the problem with regard to trauma patients and the phenomenon of occult pneumothoraces was attributable to the fact that the chest radiographs were often taken supine, suboptimally, and soon after arrival, whereas chest injury may take time to become apparent. They found that pneumothorax was the most commonly missed abnormality on chest radiography in their study of 100 trauma patients.¹³ Occult pneumothorax has also been described in medical patients. Carr *et al* in a case series of nine patients with bullous emphysema on whom they performed CT as part of the preoperative assessment of bullous emphysema found it to be useful in assessing the extent of the disease and coincidentally they noted one of the patients had an occult pneumothorax.¹⁴

Tagliabue in a review of 74 ARDS patients found an occult pneumothorax rate of one in three. Interestingly ineffective position of the thoracostomy tube was found in 13 of 20 patients.¹⁵

SUGGESTED SOLUTIONS

What are the investigation options in patients with a possible pneumothorax particularly with chronic lung disease.

Chest radiography

As previously stated, occult pneumothorax is a pneumothorax identified by CT scan but not seen on conventional radiographs.¹⁶ Carr *et al* in a cadaveric study found that the

ability of radiologists to diagnose pneumothorax varied with cadaver position and was dependent on the volume of air. The left lateral decubitus view was apparently the most sensitive for diagnosing pneumothorax on plain radiographs.¹⁷

Kollef *et al* in their prospective case series of 464 adult ICU patients found that atypical radiographic location of the pneumothorax contributed to the failure to diagnose it initially.¹⁸ In common with other authors Kolleff recommended obtaining additional views, such as cross table lateral, lateral decubitus, or full expiratory views.^{17 19 20} Jantsch *et al* in their study on 55 ICU patients with sudden deterioration of gas exchange and negative AP chest radiography found that in 14 (33%) of 42 cases a tangential view revealed a pneumothorax.²¹

Thoracic ultrasonography

Lichtenstein *et al* reported a study in which they described and evaluated lung sliding, an ultrasound finding the absence of which was seen in all 43 (100%) cases of pneumothorax. They concluded that ultrasound was a sensitive test to detect pneumothorax.²² Goodman *et al* in a prospective blinded study comparing CT, ultrasound, and erect chest radiography after 41 CT guided biopsies found ultrasound more sensitive than erect chest in the detection of pneumothorax.²³ Lichtenstein *et al* in a prospective clinical study found that vertical ultrasound artefacts (comet tail artefact) present at time of ultrasound was not found if a pneumothorax was present.²⁴

Ultrasound may therefore have a useful role in early diagnosis of occult pneumothorax particularly in the form of bedside ultrasonography, which may facilitate rapid diagnosis and localisation of the pneumothorax in the resuscitation room.

Computed tomography

Bungay *et al* in a study of 88 consecutive CT guided lung biopsies found that CT was more sensitive as it detected 35 pneumothoraces as compared with the 22 that were picked up by chest radiograph. CT picked up smaller and shallower pneumothoraces than conventional chest radiography.²⁵ Phillips *et al* in their article on the role of CT in the management of pneumothorax in patients with complex cystic lung disease advocated the use of CT in such patients when they become acutely breathless and the plain radiograph either fails to reveal the presence of a pneumothorax, although one is suspected, or fails to provide sufficient information to allow management decisions to be made.⁶

TREATMENT OPTIONS

The treatment of primary pneumothorax has been controversial since the 1960s. Patients with severe breathlessness or those with signs consistent with a tension pneumothorax obviously require immediate drainage.²⁶

The major complication of any pneumothorax is the potential for a tension pneumothorax to develop that may be rapidly fatal and must be excluded immediately in all patients regardless of aetiology.²⁷ The British Thoracic Society have defined a tension pneumothorax as any pneumothorax with cardiorespiratory collapse and they advise immediate decompression.³⁰ In patients with minimal pulmonary reserve, even a small pneumothorax can have adverse haemodynamic effects or cause tension that rapidly induces cardiovascular collapse and death.^{18 29-31} Baumann *et al* note that the physiological hallmark of tension pneumothorax is that intrapleural pressure exceeds the atmospheric pressure throughout the respiratory cycle. They also warn that previous studies have shown a fourfold increase in deaths when the treatment of the tension pneumothorax was delayed awaiting radiographic confirmation.³²

In a patient with an occult pneumothorax without significant cardiorespiratory compromise the aims of treatment are

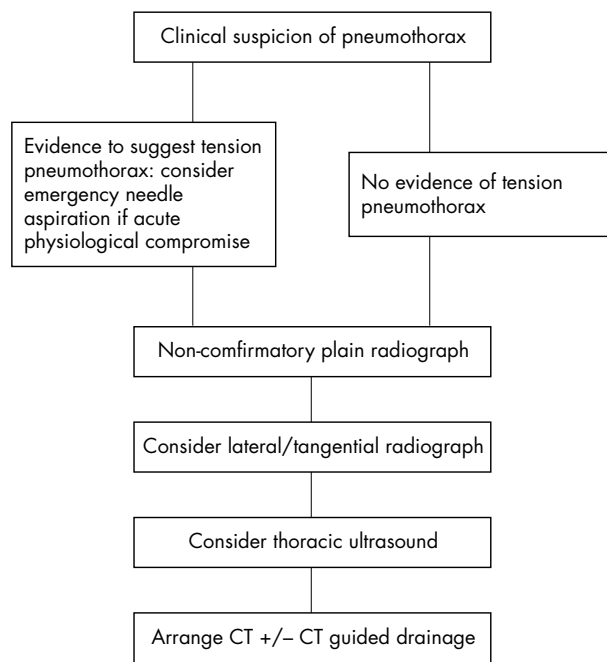


Figure 3 Suggested algorithm for management of occult pneumothorax.

the same as for spontaneous pneumothorax. Baumann *et al* defined the goals of treatment of a pneumothorax as eliminating intrapleural air, facilitating pleural healing, and attempting recurrence prevention.³³

Sahn and Heffner in their review of spontaneous pneumothorax listed the therapeutic modalities available as follows:

- Simple observation
- Supplemental oxygen (this accelerates the reabsorption of air by the pleura by a factor of four, which occurs at a rate of 2% per day in patients breathing room air.)
- Simple aspiration with a catheter, with immediate removal of the catheter after the pneumothorax has been evacuated.
- Chest tube insertion
- Pleurodesis
- Thoracoscopy
- Video assisted thoracoscopic surgery
- Thoracotomy and pleural surgery³⁴

Occult pneumothorax may create its own therapeutic problems. Reinhold *et al* in a retrospective study of 42 consecutive patients who underwent percutaneous catheter drainage of pleural collections concluded that ease of placement, comparable success rate, and safety of radiologically placed catheters make them an attractive alternative to surgically placed chest tubes.³⁵ With regard to the removal of drainage devices in occult pneumothorax, failure to detect a pneumothorax on conventional radiographs should not be among the criteria for removal. As seen by our patient's in hospital course if possible CT resolution should be confirmed.

WHAT TO DO IN THE RESUSCITATION ROOM

If tension pneumothorax is suspected it should be treated with immediate decompression. If needle decompression fails then consider an alternative site of insertion of the needle or image guided definitive drainage. When the occult pneumothorax is not under tension CT scan will help to guide treatment. Phillips *et al* in their article on the role of CT in the management of pneumothorax in patients with complex cystic lung disease advocated the use of CT in such patients

when they become acutely breathless and the plain radiograph either fails to reveal the presence of a pneumothorax, although one is suspected, or fails to provide sufficient information to allow management decisions to be made.⁶

Figure 3 shows a suggested algorithm for the treatment of occult pneumothorax.

Contributors

Peadar Gilligan treated the patient, initiated the review, and wrote the paper. He also acts as guarantor for the paper. Deirdre Hegarty advised on the structure and content and edited the paper. Dr Taj Hassan contributed to the writing and formulation of the review and advised on its structure and edited the paper.

Authors' affiliations

P Gilligan, T B Hassan, Department of Accident and Emergency Medicine, The Leeds General Infirmary, Leeds, UK
D Hegarty, Family practitioner, Leeds

Correspondence to: Dr P Gilligan, The Leeds General Infirmary, Great George Street, Leeds LS1 3EX, UK; hegartydeirdre@ireland.com

Accepted for publication 2 October 2002

REFERENCES

- 1 Henschke CI, Yankelevitz DF, Wand A, *et al*. Accuracy and efficacy of chest radiography in the intensive care unit. *Radiol Clin North* 1996;**34**:21–31.
- 2 Spizarny DL, Goodman LR. Air in the minor fissure: a sign of right-sided pneumothorax. *Radiology* 1986;**160**:329–31.
- 3 Yule SM, Hamilton JRL, Windebank KP. Recurrent pneumomediastinum and pneumothorax in Langerhans Cell Histiocytosis. *Med Pediatr Oncol* 1997;**29**:139–42.
- 4 Bianchi M, Cataldi M. Pneumothorax secondary to pulmonary Histiocytosis X. *Minerva Chir* 1999;**54**:531–6.
- 5 Lacronique J, Roth C, Battesti JP, *et al*. Chest radiological features of pulmonary histiocytosis X: a report based on fifty adult cases. *Thorax* 1982;**37**:104–9.
- 6 Phillips GD, Trotman-Dickenson B, Hodson ME, *et al*. Role of CT in the management of pneumothorax in patients with cystic lung disease. *Chest* 1997;**112**:275–8.
- 7 Gore RM, Port RB, Fry WJ. Spontaneous pneumothorax in a patient with honeycomb lung. *Chest* 1981;**2**:215–16.
- 8 Brasel KJ, Stafford RE, Weigelt JA, *et al*. Treatment of occult pneumothoraces from blunt trauma. *J Trauma* 1999;**46**:987–91.
- 9 Garramone RR, Jacobs LM, Sahdev P. An objective method to measure and manage occult pneumothorax. *Surg Gynecol Obstetr* 1991;**173**:257–61.
- 10 Wolfman NT, Myers WS, Glauser SJ, *et al*. Validity of CT classification on management of occult pneumothorax: a prospective study. *AJR* 1998;**171**:1317–20.
- 11 Tocino IM, Miller MH, Frederick PR, *et al*. CT detection of occult pneumothorax in head trauma. *AJR* 1984;**143**:987–90.
- 12 Chon KS, van Sonnenberg E, D'Agostino HB, *et al*. CT guided catheter drainage of loculated thoracic air collections in mechanically ventilated patients with acute respiratory distress syndrome. *AJR* 1999;**173**:1345–50.
- 13 Hehir MD, Hollands MJ, Deane SA. The accuracy of the first chest X-ray in the trauma patient. *Aust N Z J Surg* 1990;**60**:529–32.
- 14 Carr D, Pride NB. Computed tomography in pre-operative assessment of bullous emphysema. *Clin Radiol* 1984;**35**:43–5.
- 15 Tagliabue M, Casella TC, Zincone R, *et al*. CT and chest radiography in the evaluation of adult respiratory distress syndrome. *Acta Radiol* 1994;**35**:230–4.
- 16 Knisley BL, Kuhlman JE. Radiographic and computed tomography (CT) imaging of complex pleural disease. *Crit Rev Diagn Imaging* 1997;**38**:1–58.
- 17 Carr JJ, Reed JC, Choplin RH, Pope TL, *et al*. Plain and computed radiography for detecting experimentally induced pneumothorax in cadavers: implications for detection in patients. *Radiology* 1992;**183**:193–9.
- 18 Kolley M.H. Risk factors for the misdiagnosis of pneumothorax in the intensive care unit. *Crit Care Med* 1991;**19**:906–10.
- 19 Cooke DA, Cooke JC. The supine pneumothorax. *Ann R Coll Surg Engl* 1987;**69**:130–4.
- 20 Ziter FMH, Westcott JL. Supine subpulmonary pneumothorax. *AJR* 1981;**137**:699–701.
- 21 Jantsch H, Winkler M, Pichler W, *et al*. Pneumothorax in intensive care patients value of tangential views. *Rof. Fortschritte auf dem Gebiete der Rontgenstrahlen und der Neuen Bildgeben Verfahren* 1990;**153**:257–7.
- 22 Lichtenstein DA, Menu Y. A bedside ultrasound sign ruling out pneumothorax in the critically ill. Lung sliding. *Chest* 1995;**108**:1345–8.

- 23 **Goodman TR**, Traill ZC, Phillips AJ, *et al.* Ultrasound detection of pneumothorax. *Clin Radiol* 1999;**54**:736–9.
- 24 **Lichtenstein D**, Meziere G, Biderman P, *et al.* The comet-tail artifact: an ultrasound sign ruling out pneumothorax. *Intensive Care Med* 1999;**25**:383–8.
- 25 **Bungay HK**, Berger J, Traill ZC, *et al.* Pneumothorax post CT-guided lung biopsy: a comparison between detection on chest radiographs and CT. *Br J Radiol* 1999;**72**:1160–3.
- 26 **Harvey J**, Prescott RJ. Simple aspiration versus intercostal tube drainage for spontaneous pneumothorax in patients with normal lungs. *BMJ* 1994;**309**:1338–9.
- 27 **Vukich DJ**. Diseases of the pleural space. *Emerg Med Clin North Am* 1989;**7**:309–24.
- 28 **Miller AC**, Harvey JE on behalf of the Standards of Care Committee, British Thoracic Society. Guidelines for the management of spontaneous pneumothorax. *BMJ* 1993;**307**:114–16.
- 29 **Gobien RP**, Reines HD, Schabel SI. Localized tension pneumothorax: unrecognized form of barotrauma in adult respiratory distress syndrome. *Radiology* 1982;**142**:15–19.
- 30 **Ross IB**, Fleischer DM, Brown RA. Localized tension pneumothorax in patients with adult respiratory distress syndrome. *Can J Surg* 1994;**37**:323–8.
- 31 **Mines D**, Abbuhl S. Needle thoracostomy fails to detect a fatal tension pneumothorax. *Ann Emerg Med* 1993;**22**:863–6.
- 32 **Baumann MH**, Sahn SA. Tension pneumothorax: diagnostic and therapeutic pitfalls. *Crit Care Med* 1993;**21**:177–8.
- 33 **Baumann MH**, Strange C. Treatment of spontaneous pneumothorax. A more aggressive approach? *Chest* 1997;**112**:789–804.
- 34 **Sahn SA**, Hefner JE. Spontaneous pneumothorax. *N Engl J Med* 2000;**342**:868–74.
- 35 **Rheinhold C**, Illeseas FF, Atri M, *et al.* Treatment of pleural effusions and pneumothorax with catheters placed percutaneously under imaging guidance. *AJR* 1989;**152**:1189–91.

Caesarean delivery during maternal cardiopulmonary resuscitation for status asthmaticus

S Lurie, Y Mamet

Emerg Med J 2003;**20**:296–297

A patient who sustained a recurrent cardiopulmonary resuscitation due to status asthmaticus during one pregnancy followed by a birth of an apparently normal infant is described. Promptly performed caesarean delivery might have saved the mother and her infant. Cardiopulmonary resuscitation is less effective in a near term pregnant woman.

Although most of the ancient cultures contain legends of postmortem caesarean delivery, there were the Roman kings who formally established postmortem caesarean by the law. Later, when the ancient Rome became Roman Empire, the “*Lex Regia*” became “*Lex Caesarea*”. In fact, one of the commonest explanations for the origin of the term “caesarean section” comes from this law.¹ The ancients permitted a postmortem caesarean section as it could sometimes save fetal life after the mother’s death. Still, infant survival was rare.² The term “peritmortem” caesarean section is applied to cases where the mother was on cardiopulmonary resuscitation before the caesarean section and showed no signs of recovery afterwards.¹ Today, the most common cause for peritmortem or postmortem caesarean section is a road accident.^{1,2} Maternal survival after caesarean section performed during cardiopulmonary resuscitation is extremely rare.³ We describe a case of maternal and infant’s survival after caesarean section performed during cardiopulmonary resuscitation due to status asthmaticus, an infrequent cause for cardiac arrest during pregnancy.

CASE REPORT

A 37 year old woman, gravida 2 para 1, was brought by her husband to our emergency room unconscious and suffering respiratory arrest at 36 weeks’ gestation. The patient has been an asthmatic since adolescence intermittently treated with salbutamol inhalers. Her current pregnancy was uneventful until 24 weeks’ gestation. At that time, she suffered respiratory arrest and a loss of consciousness after exacerbation of asthma. Cardiopulmonary resuscitative measures

including intubation were successful and the patient was fully stabilised after a short time in intensive care unit of another hospital. She was extubated within 24 hours and discharged three days later receiving oral prednisone, which was tapered off over a week, salbutamol two puffs every four to six hours and was provided with epinephrine auto-injector (0.3 mg/0.3 ml). Since discharge until presentation she did well, and prenatal care was uneventful.

About an hour before arrival, the patient became acutely anxious and short of breath and did not respond to salbutamol inhaler. As she did not improve, the patient left home for hospital in their car, her husband driving. About three minutes before arrival, the patients’ husband injected her with the epinephrine auto-injector after he realised that she was unconscious. At arrival, cardiopulmonary resuscitation was promptly started after a complete cardiopulmonary arrest was recorded. The patient was stabilised after 5–10 minutes of extensive advanced cardiopulmonary resuscitative measures including intubation and defibrillation. At that time the fetus was evaluated and noted to have a heart rate of about 60 beat/minute. An emergency caesarean was accomplished and a male newborn weighing 2780 g with Apgar score of 0 at one minute was delivered. A successful cardiopulmonary resuscitation was promptly started with initial pH of 6.98 and Apgar score of 8 at five minutes. The newborn subsequently did well. The mother was extubated 36 hours after presentation and suffered no longlasting ill effects except for intentional and positional tremor. Repeated maternal echocardiogram was normal.

DISCUSSION

Cardiac arrest occurs rarely in pregnancy. Only few cases of pregnancy outcome after life threatening status asthmaticus have been described. Only three maternal deaths attributed to asthma are described in a review of the 188 reported cases of postmortem caesarean with surviving infants.² A case of life threatening status asthmaticus at 12.5 weeks’ gestation with birth of a normal full term infant after a successful resuscitation was reported.³ An improvement of uncontrollable cases of life threatening status asthmaticus after termination of pregnancy by caesarean was also reported.⁴

It is important to recognise that cardiopulmonary resuscitation is less effective in a near term pregnant woman. To diminish the effects of right lateral uterine displacement, a pregnant woman needs to be placed in a left lateral tilt during cardiopulmonary resuscitation.³ Relieving vena cava occlusion allows chest compression to provide sufficient cardiac output to facilitate cardiopulmonary resuscitation.³ In recently described case reports,^{5,6} advanced cardiopulmonary resuscitative measures were unresponsive until caesarean delivery was instituted. This implies that caesarean section might be necessary to accomplish a successful resuscitation even in case of a dead fetus. A perimortem caesarean started within four minutes of maternal cardiac arrest will yield the highest rates of maternal survival regardless of its cause.¹

Electric cardioversion during pregnancy has been described in the literature and seems safe for the fetus.^{7,8} The physiological changes in pregnancy do not change defibrillation energy requirements for adult defibrillation.⁹

The outcome in our case was successful because of left lateral tilt position of the mother during cardiopulmonary resuscitation and rapid decision to perform a caesarean section.

We report this case because it calls attention to an acute condition that may be seen only once over the course of a busy career of practicing physician. The critical period in management of a pregnant patient with cardiopulmonary arrest attributable to status asthmaticus is within the first several minutes of the event. It is important to recognise that promptly performed caesarean delivery may save the mother and her infant. The case of this patient is unique in view of the fact that she sustained a recurrent cardiopulmonary resuscitation attributable to status asthmaticus during one pregnancy followed by a birth of an apparently normal infant.

Three women in a car

S Satchithananda

Isolated sternal fractures have been increasing in number since the advent of seat belt legislation in 1983.¹ The management of these patients has been a matter of debate for some time. These cases demonstrate that other coexistent pathology may be difficult to identify at the time of presentation and that a high level of suspicion for other injuries is necessary. Three women presented to the emergency department after a collision between their car travelling at 45 miles per hour and a stationary van.

CASE 1

The 71 year old restrained driver of the car presented complaining of chest pain and tenderness. Previous medical history included osteoporosis and long term corticosteroid use for asthma. Initial observations, examination, chest radiograph, and electrocardiogram were normal. A sternal radiograph demonstrated a fracture of the sternum. A brief episode of hypotension was noted (systolic blood pressure of 90) but thought to be vagal and the patient was later discharged home with oral analgesia.

CASE 2

The 77 year old restrained front seat passenger also presented with chest pain and tenderness. Initial observations, chest

Contributors

Samuel Lurie performed the caesarean section during the cardiopulmonary resuscitation, reviewed the literature, participated in discussion of core ideas and writing the paper, and acts as guarantor of the paper. Yaakov Mamet participated in discussion of core ideas, edited the paper, and also acts as guarantor of the paper.

Authors' affiliations

S Lurie, Y Mamet, Department of Obstetrics and Gynaecology, Laniado Hospital, Netanya, Israel

Correspondence: Dr S Lurie, Department of Obstetrics and Gynaecology, Edith Wolfson Medical Centre, Holon, Israel; drslurie@hotmail.com

Accepted for publication 14 June 2002

REFERENCES

- 1 Whitten M, Irvine LM. Postmortem and perimortem caesarean section: what are the indications? *J R Soc Med* 2000;**93**:6-9.
- 2 Katz VL, Dotters DJ, Droegemueller W. Perimortem cesarean delivery. *Obstet Gynecol* 1986;**68**:571-6.
- 3 Gilchrist DM, Friedman JM, Werker D. Life-threatening status asthmaticus at 12.5 weeks' gestation. Report of a normal pregnancy outcome. *Chest* 1991;**100**:285-6.
- 4 Gelber M, Sidi Y, Gassner S, et al. Uncontrollable life-threatening status asthmaticus - an indicator for termination of pregnancy by cesarean section. *Respiration* 1984;**46**:320-2.
- 5 Cardosi RJ, Porter KB. Caesarean delivery of twins during maternal cardiopulmonary arrest. *Obstet Gynecol* 1998;**92**:695-7.
- 6 O'Connor RL, Sevarino FB. Cardiopulmonary arrest in the pregnant patient: a report of successful resuscitation. *J Clin Anesth* 1994;**6**:66-8.
- 7 Schroeder JS, Harrison DC. Repeated cardioversion during pregnancy. Treatment of refractory paroxysmal atrial tachycardia during 3 successive pregnancies. *Am J Cardiol* 1971;**27**:445-6.
- 8 Brown O, Davidson N, Palmer J. Cardioversion in the third trimester of pregnancy. *Aust N Z J Obstet Gynaecol* 2001;**41**:241-2.
- 9 Nanson J, Elcock D, Williams M, et al. Do physiological changes in pregnancy change defibrillation energy requirements? *Br J Anaesth* 2001;**87**:237-9.

Emerg Med J 2003;**20**:297-298

radiograph and electrocardiogram were also normal. A fractured sternum was confirmed on radiography. The patient required intravenous opioids as analgesia and as she lived alone she was admitted to the emergency department observation ward overnight.

Over the next 16 hours she developed an ileus. After a normal CT scan of her abdomen she was managed conservatively and discharged home after three days. Her CT scan demonstrated a small right sided pleural effusion not evident on initial chest radiograph or clinical examination.

Box 1 ECG abnormalities of myocardial contusion¹⁰ Possible ECG findings

Unexplained sinus tachycardia
Arrhythmias and conduction abnormalities
ST segment changes
- non-specific in myocardial injury
- concave ST segment classical of pericarditis (may be associated with low voltage complexes)

Box 2 Chest radiograph abnormalities associated with sternal fracture**Possible chest radiograph findings****Chest trauma**

- Haemothorax
- Pneumothorax
- Clavicle/rib fractures
- Surgical emphysema
- Pulmonary contusion
- Increased cardiothoracic ratio suggestive of haemopericardium
- Widened mediastinum (may indicate retrosternal haematoma or mediastinal great vessel injury)
- Pneumomediastinum/pneumopericardium

Associated injuries

- Fractures of thoracic spine
- Pneumoperitoneum

Table 1 Incidence of injuries associated with sternal fracture (adapted from Brookes *et al*⁹)

Injury	Incidence (%)
Fracture	
Clavicle	5.2
Rib 1 or 2	5.9
Rib 3–12	21.3
Cervical	2.2
Thoracic	4.8
Lumbosacral	3.3
Pelvis	2.2
Limb	16.9
Skull/face	3.7
Pulmonary	
Pneumothorax	3.3
Haemothorax	5.9
Contusion	3.7
Loss of consciousness	20.6
Abdominal	3.3

CASE 3

This 77 year old restrained rear seat passenger of the car was also complaining of chest pain and tenderness. The initial observations, examination, and chest radiograph were normal and her electrocardiogram showed a left bundle branch block morphology (although the patient reported no known cardiac history). A radiograph of her sternum demonstrated a fracture. During the administration of intravenous morphine for analgesia a hypotensive episode was observed. This patient was therefore referred to the surgical team and despite repeated examination no abnormality was found. The following morning a repeated haemoglobin estimation showed a fall from 9.3 g/dl on admission to 6.9g/dl. An ultrasound of the abdomen demonstrated free fluid and at exploratory laparotomy later that day a splenectomy was performed for a capsular tear of her spleen.

DISCUSSION

Advanced Trauma Life Support² advocates awareness of the risk of blunt cardiac injury and pulmonary contusions associated with sternal fractures during the assessment for multisystem injury.

Many authors have written regarding the incidence of complications in isolated sternal fractures and whether admission of these patients is warranted. Most studies have been retrospective in design and therefore do not address the difficulty in initial assessment to rule out other injuries. Sadaba *et al*³ published a review article in May 2000 identifying the problem of wide regional variations in the management of isolated sternal fractures in the United Kingdom. The authors suggested guidelines for the management of isolated sternal fractures implying that if a chest radiograph and electrocardiogram were normal on admission (in a patient without underlying cardiorespiratory disease) and adequate analgesia was achieved then that patient may be appropriate for discharge to a home environment. Evidence of complications of sternal injury may be evident on ECG or chest radiograph (boxes 1 and 2) but normal investigations do not necessarily imply that the fracture is an isolated injury. Most articles advocating discharge from accident and emergency focus on the low incidence of cardiac complications associated with sternal fractures.^{4–8} Unintentionally these papers may have led to a perception that patients with presumed isolated sternal fractures may be safe to discharge from the emergency department. Considering the high incidence of associated injuries demonstrated by Brookes *et al*⁹ (table 1) (a prospective

study of a series of 272 patients in which 54.7% with sternal fractures had other skeletal or visceral injuries) we should continue to be vigilant in our assessment of this group of patients.

The cases reported here show that early identification of “isolated” sternal fractures may be difficult and that in fact two of these three cases had significant complications warranting further investigation despite minimal symptoms and signs at the time of presentation. A sternal fracture is an indicator of significant blunt injury to the patient and should therefore be treated with a high degree of suspicion and a careful search for other injuries made. The “isolated sternal fracture” may be a diagnosis only safely made retrospectively after a period of observation.

Contributors

Dr S Satchithananda researched and wrote the case report. Mr B Roy, emergency medicine consultant at Peterborough District Hospital, kindly reviewed the manuscript.

Author's affiliations

S Satchithananda, Emergency Department, Queen Elizabeth Hospital, Gayton Road, Kings Lynn, Norfolk PE30 4ET, UK

Correspondence to: Dr S Satchithananda; sue.satchi@doctors.org.uk

Accepted for publication 2 October 2002

REFERENCES

- 1 **Budd JS**. Effect of seatbelt legislation on the incidence of sternal fractures seen in the accident department. *BMJ* 1985;**291**:785.
- 2 **American College of Surgeons Committee on Trauma**. *Advanced trauma life support for doctors*. 6th edn. Chicago: American College of Surgeons, 1997.
- 3 **Sadaba JR**, Oswal D, Munsch CM. Management of isolated sternal fractures: determining the risk of blunt cardiac injury. *Ann R Coll Surg Engl* 2000;**82**:162–6.
- 4 **Jackson M**, Walker WS. Isolated sternal fracture: a benign injury? *Injury* 1992;**23**:535–6.
- 5 **Wright SW**. Myth of the dangerous sternal fracture. *Ann Emerg Med* 1993;**22**:1589–92.
- 6 **Bu'lock FA**, Prothero A, Shaw C, *et al*. Cardiac involvement in seatbelt related and direct sternal trauma. A prospective study and management implications. *Eur Heart J* 1994;**15**:1621–7.
- 7 **Johnson I**, Branfoot T. Sternal fractures—a modern review. *Arch Emerg Med* 1992;**10**:24–8.
- 8 **Peek GJ**, Firmin RK. Isolated sternal fractures: an audit of 10 years' experience. *Injury* 1995;**26**:385–8.
- 9 **Brookes JG**, Dunn RJ, Rogers IR. Sternal fractures: a retrospective analysis of 272 cases. *J Trauma* 1993;**35**:46–54.
- 10 **Braunwald E**. *Heart disease: a textbook of cardiovascular medicine*. 5th edn. Philadelphia: WB Saunders, 1997.

Temperate pyomyositis in an injecting drug misuser. A difficult diagnosis in a difficult patient

M Crossley

Emerg Med J 2003;**20**:299–300

The medical care of injecting drug misusers presents many challenges. Though they can be awkward and unreliable they are at risk of serious medical conditions not often seen in the general population. This case report illustrates some of the difficulties in the diagnosis and treatment of a patient with pyomyositis associated with heroin injection.

A 32 year old man attended the emergency department on the advice of his general practitioner complaining of abdominal pain and vomiting, fresh rectal bleeding, haematuria, and low back pain. He had noticed a swelling on the left side of his lower back, which had become so painful he was barely mobile. He had been injecting heroin for about seven years and had been feeling unwell for two weeks after accidental extravascular injection into his left groin. On closer questioning he admitted to having back pain and requiring elbow crutches to walk for over a year.

On examination he had a temperature of 35.2°C, pulse of 105, respiratory rate of 20, and blood pressure of 100/50. He was dehydrated and looked unwell. He had a fluctuant swelling about 15 cm in diameter on the left side of his lower back, which extended across his sacrum. He was tender over both his greater trochanters. A clinical diagnosis of septicaemia secondary to an abscess was made. As it was not possible to arrange immediate computed tomography the patient was referred to the general surgeons.

The surgical registrar diagnosed septic arthritis involving both hips and sacroiliac joints and advised referral to the orthopaedic surgeons. Orthopaedic opinion was that there was no evidence of septic arthritis in his hips and referred him back to the care of the emergency department. Finally, four hours after arrival, he was admitted to the acute medical ward.

Computed tomography showed a large left sided gluteal abscess (fig 1) communicating through the left sacroiliac joint with the retroperitoneal space (fig 2) and tracking up to the lower pole of the left kidney. Under computed tomographic guidance on day two, two catheters were inserted into the retroperitoneal space and fresh pus drained freely. Blood cultures grew *Staphylococcus aureus*.

On day 10, repeat computed tomography showed that the abscess, though smaller, contained persistent locules, the left sacroiliac joint remained diastased by pus and there were further locules of pus in the rectospinal musculature. On day 14, he was transferred to the care of the orthopaedic department for open drainage of the abscess and the left sacroiliac joint. He required a further five general anaesthetics for changes of pack and drain removal. On day 64 he was discharged home.

MEDICAL HISTORY

On review of notes it was found that, in the 13 months before this admission, he had attended the emergency department three times and been admitted to hospital twice. He had also been seen in the orthopaedic outpatient department. His initial contact had been an admission, arranged by his general practitioner, when he had a left calf deep venous thrombosis and associated cellulitis. At that time, *S aureus* was isolated from blood cultures. He was treated with oral flucloxacillin and tinzaparine. He failed to attend for follow up.

Five months later he attended the emergency department with a temperature and low back pain. A diagnosis of psoas abscess was made and he was admitted to the acute medical ward. He absconded from the ward before being seen. The blood cultures that had been taken in the emergency department once again grew *S aureus*. Attempts made to contact the patient failed as he had lost touch with his family, his phone had been disconnected, and he was no longer registered with a general practitioner. It is interesting to note that the card from this attendance was missing from his emergency department notes, and the blood culture report was filed in the hospital notes only. This information was therefore not available to emergency department staff when he next attended.

Six weeks later he returned to the emergency department complaining of nausea, vomiting, and back pain. He was again admitted under the physicians with a provisional diagnosis of pyelonephritis with muscular back pain. At this stage his haemoglobin was 9.3 g/dl. He subsequently had a normal upper gastrointestinal endoscopy. Once again he developed a deep venous thrombosis. *S aureus* was again isolated on blood cultures. He was discharged prescribed trimethoprim, flucloxacillin, and warfarin.

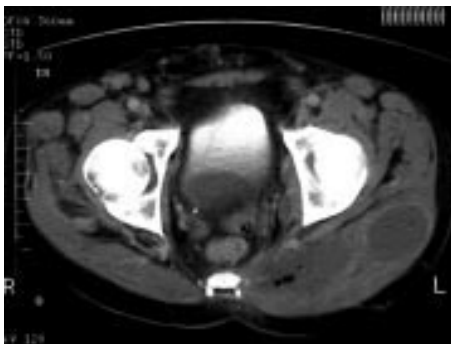

Figure 1

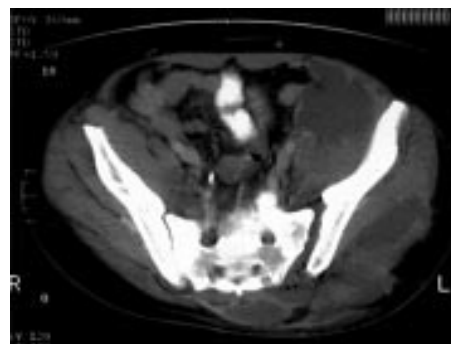


Figure 2

After a further six weeks he re-presented to the emergency department with low back pain. His temperature was normal. A diagnosis of muscular pain was once again made. The following week he was seen in the orthopaedic outpatient department, having been referred by his general practitioner for investigation of the persistent low back pain. He was referred for physiotherapy and failed to attend for further follow up.

His next attendance five months later was the episode described initially.

DISCUSSION

Pyomyositis is a primary bacterial infection of skeletal muscle. It is common in the tropics (tropical pyomyositis), first being described by Scriba in 1885.¹ It was first reported in the USA in 1971,² when the term temperate pyomyositis was introduced. Between 1971 and 1986 fewer than 50 cases of temperate pyomyositis were reported.³ With the increasing prevalence of immunocompromised patients and injecting drug misusers it is becoming more widely recognised in temperate countries.⁴ It is commonly misdiagnosed in its initial stages.⁵ The most common muscle groups to be involved are iliopsoas (46%), gluteals (18%), and the thigh (18%).⁶ *S aureus* is the most frequently isolated organism,^{3,4,6} occurring in over 90% of patients in some series.⁴ Other organisms implicated include *S pyogenes*, *S freundii*, and *E coli*.^{3,4,6} Recognised predisposing factors are trauma, HIV infection, diabetes mellitus, corticosteroid treatment, malignancy, and intramuscular injection.

Pyomyositis presents in three stages. Initially there is myositis and muscle oedema but no abscess formation. The patient presents with muscle pain and low grade fever. At this stage the condition may be cured by appropriate antibiotic therapy, but it is difficult to diagnose because of non-specific signs and symptoms.⁵ The most common stage at presentation is stage two, characterised by abscess formation, muscle pain, fever, tenderness, and leucocytosis. This picture is complicated in stage three disease by systemic toxicity. Treatment in the latter stages requires surgical drainage as well as appropriate antibiotics.⁶

This case highlights some of the difficulties posed in managing the health needs of drug misusers. It seems probable that the extensive abscesses seen in this patient had been developing over at least 13 months. In this time he had been seen in the hospital on no less than five separate occasions. A combination of factors contributed to the delay in diagnosis. As previously mentioned temperate pyomyositis is often misdiagnosed initially.⁵ Having been admitted, the patient absconded from the ward, failed to keep follow up appointments, had been removed from his GP's list, and was at times

uncontactable. However, some of the responsibility must rest with the medical teams involved in his care. Incomplete medical records and poor communication between medical specialties, surgical specialties, and the emergency department regarding inpatient investigations and blood cultures resulted in lost opportunities to reinstate appropriate inpatient care.

If the emergency department were to routinely receive and file copies of discharge letters for patients admitted through the department, we would have been aware that on his second admission a diagnosis of psoas abscess had been made, and *S aureus* had been isolated from blood cultures. This should have enabled him to be rapidly readmitted under the appropriate specialty.

Computer based records should reduce the incidence of notes "going missing" and enable all hospital and perhaps primary care staff to access investigations performed and treatment received by any patient.

It is important for all medical staff who may come into contact with injecting drug misusers to be aware of the range of conditions with which they may present and receive adequate training in dealing with patients who refuse treatment. This should result in more timely and appropriate treatment, and ultimately reduce morbidity.

ACKNOWLEDGEMENTS

With thanks to Dr Richard Lynch for help with the preparation of this article, and to Mr Paul Grout for support with the original idea.

.....

Funding: none.

Conflicts of interest: none.

Correspondence to: Dr M Crossley, Accident and Emergency Department, Hull Royal Infirmary, Anlaby Road, Hull HU3 2JZ, UK

Accepted for publication 16 July 2002

REFERENCES

- 1 Scriba J. Beitrag zur aetiologie der myositis acuta. *Dtsch Z Chir* 1885;**22**:497-507.
- 2 Levin MJ, Gardener P, Waldvogel FA. 'Tropical' pyomyositis: an unusual infection due to *Staphylococcus aureus*. *N Engl J Med* 1971;**284**:196-8.
- 3 Rodgers WB, Yodkowski ML, Mintzer CM. Pyomyositis in patients who have the human immunodeficiency virus. *J Bone Joint Surg* 1993;**75-A**:588-91.
- 4 Gibson RK, Rosenthal SJ, Lukert BP. Pyomyositis. Increasing recognition in temperate climates. *Am J Med* 1984;**77**:786-72.
- 5 Hall RL, Callaghan JJ, Moloney E, et al. Pyomyositis in a temperate climate. *J Bone Joint Surg* 1990;**72-A**:1240-3.
- 6 Ciampi MA, Sadigh M, Sherwood JA, et al. Temperate pyomyositis at two community hospitals. *Infectious Disease in Clinical Practice* 1998;**7**:265-73.

EMERGENCY CASEBOOK

Stridor and Down's syndrome

M Gutenstein

Emerg Med J 2003;**20**:301

A 36 year old woman with Down's syndrome and hypothyroidism presented to the emergency department with breathlessness. She had suffered with coryzal symptoms for a week, before becoming increasingly dyspnoeic the day before presentation. On arrival she was unable to speak and stridulous. She was neither drooling nor toxic. Her temperature was 37.4°C. However oxygen saturation was reduced and arterial blood gas measurement showed a type 2 respiratory failure with acidosis. An urgent anaesthetic opinion was sought, and the patient transferred to the resuscitation room. Fiberoptic laryngoscopy confirmed the suspicion of a supraglottitis. After inhalation induction using sevoflurane, intubation was achieved with difficulty. Using bougie guidance, a size 7.0 orotracheal tube was found to be too large, hence the patient was intubated with a size 6.0 orotracheal tube. Cefuroxime and dexamethasone were given, and the patient was admitted to the intensive care unit. The supraglottic inflammation was monitored by regular laryngoscopy. After seven days without significant reduction in supraglottic inflammation, formal tracheostomy was performed. Blood cultures were negative.

DISCUSSION

Infection and inflammation of the supraglottic structures may involve the epiglottis only or extend to the aryepiglottic folds and arytenoid soft tissues, causing epiglottitis and supraglottitis respectively. Although widely reported in paediatric practice before routine *H influenzae* B immunisation, supraglottitis may be under-diagnosed in adults.¹ When such patients present with signs or symptoms of respiratory distress, there is risk of life threatening complete airway obstruction. Early interventional support of the airway must be considered.² A wide variety of infections have been associated with the problem including Gram positive cocci, meningococcus, pasteurella, serratia, and herpes simplex virus. Hence a broad spectrum antibiotic is needed in the first instance. In respiratory distress, temporising measures such as humidified oxygen and helium-oxygen mixtures are suggested to be useful before formal intubation is achieved. Nebulised epinephrine and corticosteroids are often used although neither is definitively proved to be of benefit.³ Emergency cricothyroidotomy may be necessary. UK consensus among emergency anaesthetists suggests inhalation induction using sevoflurane as the best way of achieving intubation.⁴

In this case Down's syndrome provided a number of additional challenges. People with Down's syndrome are prone to respiratory infections. In addition airway problems such as obstructive sleep apnoea are common, a product of craniofacial differences in anatomy. These differences, such as macroglossia and a narrow nasopharynx, may also make intubation difficult. Studies of anaesthesia for elective surgery in Down's syndrome have reported problems with atlanto-axial instability and tracheal stenosis. It is suggested that in the patient with Down's syndrome an endotracheal tube smaller than predicted should be routinely used.⁵

LEARNING POINTS

This case highlights the importance of considering supraglottitis in the adult patient with stridor or painful dysphagia. Early airway intervention may be necessary. Furthermore, the anatomical differences associated with Down's syndrome may have an important effect on disease progression and patient outcome. Emergency staff should be aware that patients with Down's syndrome may require expert intubation with a smaller than expected endotracheal tube even in the absence of supraglottic swelling.

Funding: none.

Conflicts of interest: none.

ACKNOWLEDGEMENTS

The author thanks Dr J Kendall for his helpful comments.

Correspondence to: Dr M Gutenstein, Accident and Emergency Department, Frenchay Hospital, Bristol BS161LE, UK; doctormarco@yahoo.co.uk

Accepted for publication 1 March 2002

REFERENCES

- 1 **Stuart MJ**, Hodgetts TJ. Adult epiglottitis: prompt diagnosis saves lives. *BMJ* 1994;**308**:329-330.
- 2 **Ames WA**, Ward VM, Tranter RM, *et al*. Adult epiglottitis: an under-recognized, life-threatening condition. *Br J Anaesth* 2000;**85**:795-7.
- 3 **Dixon J**, Black JJ. Adult supraglottitis: an important cause of airway obstruction. *J Accid Emerg Med* 1998;**15**:114-15.
- 4 **Moore EW**, Davies MW. Inhalational versus intravenous induction. A survey of emergency anaesthetic practice in the United Kingdom. *Eur J Anaesthesiol* 2000;**17**:33-7.
- 5 **Shott SR**. Down syndrome: analysis of airway size and a guide for appropriate intubation. *Laryngoscope* 2000;**110**:585-92.