

PEDIATRICS®

Temporary Removal of Navel Piercing Jewelry for Surgery and Imaging Studies

Oliver J. Muensterer

Pediatrics 2004;114:384-386

DOI: 10.1542/peds.2004-0130

This information is current as of May 10, 2005

The online version of this article, along with updated information and services, is located on the World Wide Web at:

<http://www.pediatrics.org/cgi/content/full/114/3/e384>

PEDIATRICS is the official journal of the American Academy of Pediatrics. A monthly publication, it has been published continuously since 1948. PEDIATRICS is owned, published, and trademarked by the American Academy of Pediatrics, 141 Northwest Point Boulevard, Elk Grove Village, Illinois, 60007. Copyright © 2004 by the American Academy of Pediatrics. All rights reserved. Print ISSN: 0031-4005. Online ISSN: 1098-4275.

American Academy of Pediatrics

DEDICATED TO THE HEALTH OF ALL CHILDREN™



Temporary Removal of Navel Piercing Jewelry for Surgery and Imaging Studies

Oliver J. Muensterer, MD

ABSTRACT. *Background.* Navel piercings are becoming increasingly popular among adolescents. Body piercing jewelry must be removed before surgery, because electrical burns can occur with electrocauterization. Also, piercing jewelry creates artifacts during magnetic resonance imaging. Even temporary piercing jewelry removal may lead to closure of the subcutaneous tract; therefore, temporary replacement with a nonmetallic spacer is indicated.

Objective. This report describes a simple, safe, effective method for perioperative temporary replacement of navel piercing jewelry with a universally available, nonmetallic, sterile, intravenous catheter.

Methods. The umbilical piercing jewelry of 5 adolescent female patients was removed before surgical or radiologic interventions by using the following technique: 1) disinfecting the piercing and umbilical area with 70% isopropyl alcohol, 2) opening the piercing jewelry by removing the bead from the bar, 3) placing the tip of a tight-fitting intravenous catheter (14 or 16 gauge, without the needle) over the threaded tip of the bar, 4) advancing the intravenous catheter caudally, pushing the piercing out of the skin tract, and 5) removing the jewelry and leaving the intravenous catheter in the subcutaneous skin tract as a spacer. After the intervention, the piercing jewelry was reinserted by following the described steps in reverse order. The patients were evaluated after 1 week, for assessment of any adverse effects, including infection.

Results. With this method, piercing jewelry removal and reinsertion required <2 minutes for all patients. No procedural complications were noted. All jewelry was reinserted successfully after the procedure. The intravenous catheter left in situ did not interfere with surgery, and it did not produce any artifacts or adverse effects during magnetic resonance imaging. Follow-up evaluations at 1 week demonstrated no signs of irritation, infection, or other side effects of the procedure for any of the patients.

Conclusions. Perioperative removal of navel piercing jewelry with this new technique proved to be quick, feasible, and safe. Piercings in other locations on the body may be replaced for surgery or imaging studies in the same way, with minor modifications. *Pediatrics* 2004; 114:e384–e386. URL: <http://www.pediatrics.org/cgi/content/full/114/3/e384>; *piercing, jewelry, removal*.

From the Department of Pediatric Surgery, Dr von Hauner Children's Hospital, University of Munich, Munich, Germany.

Accepted for publication Mar 22, 2004.

DOI: 10.1542/peds.2004-0130

Address correspondence to Oliver J. Muensterer, MD, Department of Pediatric Surgery, Dr von Hauner Children's Hospital, University of Munich, Lindwurmstrasse 4, 80337 Munich, Germany. E-mail: oliver.muensterer@med.uni-muenchen.de

PEDIATRICS (ISSN 0031 4005). Copyright © 2004 by the American Academy of Pediatrics.

Umbilical piercing jewelry is becoming increasingly popular among adolescent patients, as a unique form of self-expression. Recent surveys indicate that >50% of undergraduate students have some form of body piercing,¹ with the navel being one of the most popular sites.

Body piercing jewelry must be removed before surgery, because electrical burns can occur when the jewelry is exposed to an electrical current during electrocauterization.² Also, piercing jewelry creates artifacts during magnetic resonance imaging³ and may pose a risk to the patient during the study.⁴ Despite the increased prevalence of piercings, health care professionals remain surprisingly ignorant regarding their periprocedural management. In 1 survey, only 6 of 28 emergency department physicians were familiar with the opening mechanisms for piercing jewelry.⁵

Depending on skin thickness and umbilical depth, navel piercings may require up to 12 months to heal.² During this time, removal of the jewelry, even for short periods of time, may lead to closure of the piercing tract. According to the Association of Professional Piercers, even well-healed piercings can shrink or close in minutes, after having been there for years.⁶ In such cases, reintroduction of the piercing jewelry can be a difficult, time-consuming task.⁷ Among our adolescent patients, closure of the subcutaneous tract and increased bleeding or infection after forced reinsertion are frequently stated concerns. This report thus describes a safe efficient technique for temporary perioperative replacement of body piercing jewelry with a universally available, nonmetallic, sterile, inexpensive, intravenous catheter.

Navel piercing jewelry usually has the shape of a bent metal barbell (Fig 1A). A curved bar connects a fixed ornament on 1 side and a removable bead on the other. Most beads are screwed onto the bar (barbell type). Captive bead ring types are closed by inserting a ball with 2 small dimples into an open ring, which holds the bead through tension (Fig 1B). For removal, a surgical clamp can be introduced to pry open the ring, so that the ball falls out. Specialized body jewelry removal tools are available.⁸ Piercing jewelry should be made of surgical steel, titanium, niobium, silver, or gold, to avoid allergic reactions against nickel.

METHODS

Piercing jewelry was removed before interventions by using the following technique (Fig 2): 1) disinfecting the piercing and um-

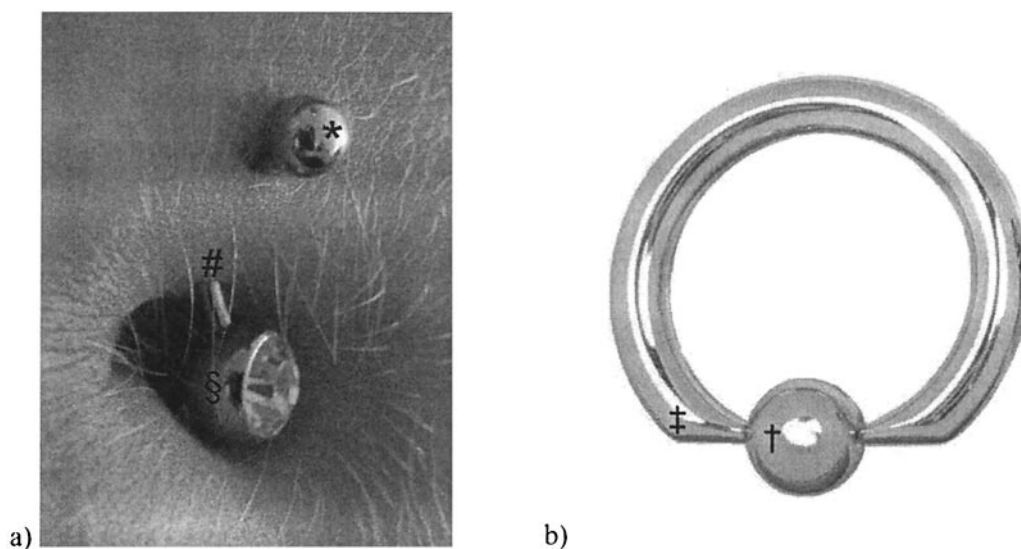


Fig 1. (a) shows a close-up view of a common type of navel piercing jewelry. The ornament (§) is permanently fixed to a curved metal bar (#). The bead (*) is screwed onto the other end of the bar, holding the jewelry in place. (b) shows a diagram of captive ring bead jewelry, in which a ball with 2 dimples (†) is held in place through the tension of the ring (‡).

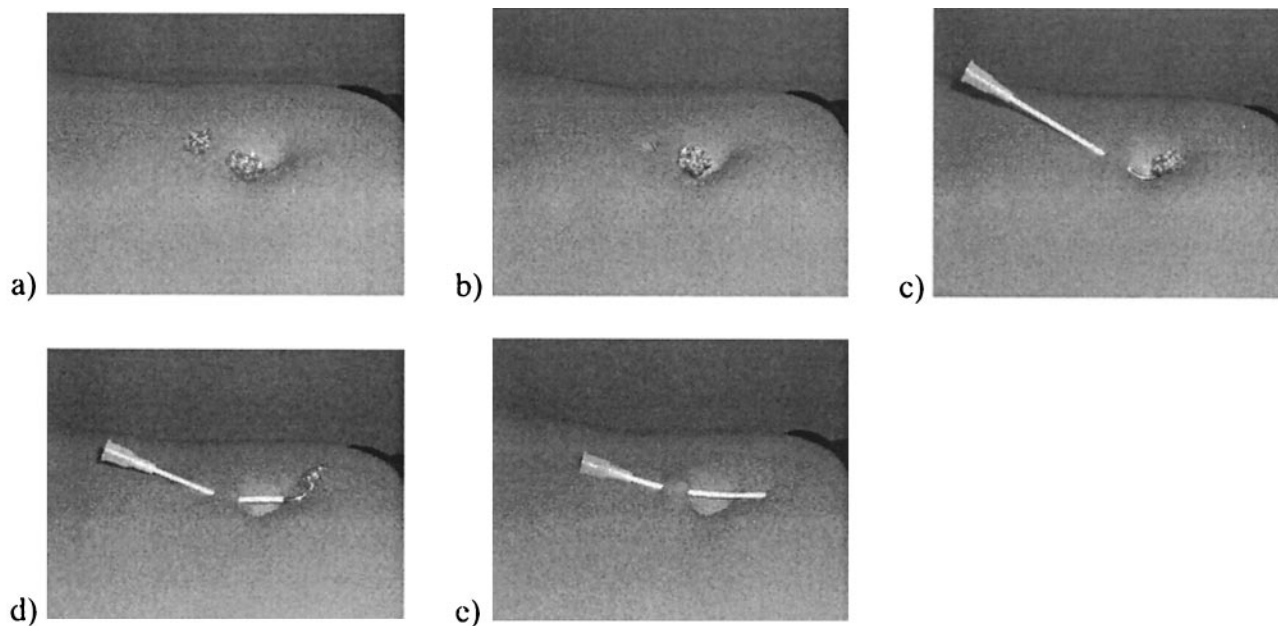


Fig 2. Technique for replacement of piercing jewelry with a sterile intravenous catheter. The area is cleansed with 70% alcohol (a), the bead is screwed off (b), an intravenous catheter is fitted over the open end (c), the piercing jewelry is pushed out of the tract on the catheter (d), and the jewelry is removed and the catheter is secured in place by covering the area and catheter with a transparent, polyurethane, bio-occlusive dressing (e).

bilical area with 70% isopropyl alcohol, 2) removing the bead by turning it counterclockwise (all beads in this study had screw-type opening mechanisms), 3) placing the tip of a tight-fitting intravenous catheter (14 or 16 gauge, without the needle) over the threaded tip of the bar, 4) advancing the intravenous catheter caudally, pushing the piercing out of the skin tract, and 5) removing the jewelry, leaving the intravenous catheter in the subcutaneous skin tract as a spacer. The catheter was secured and covered with a sterile dressing for the operation or the imaging study. Alternatively, a monofilament suture could be passed through the catheter and tied into a loop with the catheter in place, to prevent dislodgement. After the intervention, the piercing jewelry was reinserted by following the illustrated steps in reverse order.

The technique was performed for 5 adolescent female patients (age: 14–17 years). Indications for surgery were an inguinal hernia in 1 case and appendicitis in 2 cases. Two other patients underwent magnetic resonance imaging. The patients were evaluated

for any adverse effects, including infection, after 1 week. Specifically, patients were evaluated for fever, bleeding, local erythema, or purulent discharge from the umbilical piercing site.

RESULTS

The time from the initial navel piercing to periprocedural replacement with the intravenous catheter ranged from 3 weeks to 11 months. With this method, piercing jewelry removal and reinsertion required <2 minutes for all patients. No procedural complications were noted. All jewelry was reinserted successfully after the procedure. The intravenous catheter left in situ did not interfere with surgery and did not produce any artifacts or adverse effects dur-

ing magnetic resonance imaging. Follow-up evaluations at 1 week demonstrated no signs of irritation, infection, or other side effects of the procedure for any of the patients.

Furthermore, in our institution, tongue piercing jewelry was removed for anesthesia by exchanging the jewelry with an intravenous catheter in the described manner. A monofilament suture (-0-polypropylene) was threaded through the catheter, the catheter was removed, leaving the suture in place, and the suture was tied in a loop. For reinsertion of the jewelry after surgery, the loop was cut and the suture was used as a guidewire to thread a new intravenous catheter into the piercing tract. The catheter then facilitated reinsertion of the jewelry with the proposed technique.

DISCUSSION

Periprocedural removal of navel piercing jewelry with this new technique proved to be quick, feasible, and safe. The method may also be practical for temporarily replacing piercing jewelry in other anatomic regions, such as the nipples, earlobes, face, and genitals.

Because the problem of tract closure after piercing jewelry removal for surgery and imaging examinations is common, other alternatives have been described. One study proposed the use of nylon line used in lawn care equipment as a spacing device for removal of oral piercing jewelry.⁹ With this technique, a 4-cm-long piece of nylon line is cut, and 1 end is heated with a lighter or match and pressed against a flat surface, to provide a "stop." The other end is tapered with a pocketknife. For pediatricians and pediatric surgeons, however, the time and resources necessary for this procedure may not be readily available.

A plastic barbelle designed for use as a spacing device during magnetic resonance imaging is commercially available, at a moderate price.¹⁰ The device is meant to be inserted into the piercing tract by the patient before the procedure. Drawbacks are the expense and potential contamination by the nonsterile spacer. In contrast, our proposed method uses materials that are inexpensive and are universally available in medical settings (an intravenous catheter). Furthermore, the procedure can be performed by health care providers under sterile conditions.

Ideally, the initial piercing jewelry should be left in place during the entire minimal initial healing time.⁶

Despite individual variation, most piercing studios in our vicinity recommend at least 4 to 8 weeks before replacement of the starter jewelry. The shortest period from initial piercing to replacement with the intravenous catheter method in this series was 3 weeks. With the described technique, however, uncomplicated substitution should be feasible at any time.

To date, the procedure has not been used for laparoscopic surgery, during which 1 of the trocars is generally inserted at the umbilical fold. Both patients with appendicitis in this series underwent conventional appendectomies. For laparoscopic surgery, leaving a monofilament suture tied in a loop in the piercing tract might provide the necessary surgical access while keeping the tract patent.

Although literature on the subject is scarce, endocarditis associated with navel piercing has been reported for adolescents with congenital heart disease.¹¹ Standard antibiotic endocarditis prophylaxis for this procedure may be indicated for high-risk populations¹² when bacterial contamination is clinically suspected.

REFERENCES

1. Mayers LB, Judelson DA, Moriarty BW, Rundell KW. Prevalence of body art (body piercing and tattooing) in university undergraduates and incidence of medical complications. *Mayo Clin Proc.* 2002;77:29-34
2. Stirn A. Body piercing: medical consequences and psychological motivations. *Lancet.* 2003;361:1205-1215
3. Guermazi A, Miaux Y, Zaim S, Peterfy CG, White D, Genant HK. Metallic artefacts in MR imaging: effects of main field orientation and strength. *Clin Radiol.* 2003;58:322-328
4. Shellock FG. MR imaging of metallic implants and materials: a compilation of the literature. *AJR Am J Roentgenol.* 1988;151:811-814
5. Khanna R, Kumar SS, Raju BS, Kumar AV. Body piercing in the accident and emergency department. *J Accid Emerg Med.* 1999;16:418-421
6. Association of Professional Piercers. *Body and Facial Piercing Aftercare Guidelines.* Chamblee, GA: Association of Professional Piercers; 2000. Available at: www.safepiercing.org/bodyAftercare.html. Last accessed March 15, 2004
7. Marenzi B. Body piercing: a patient safety issue. *J Perianesth Nurs.* 2004;19:4-10
8. Larkin BG. Home study program: the ins and outs of body piercing. *AORN J.* 2004;79:333-342
9. Peticolas T, Tilliss TS, Cross-Poline GN. Oral and perioral piercing: a unique form of self-expression. *J Contemp Dent Pract.* 2000;1:30-46
10. MRI and x-ray piercing retainer. Available at: <http://shop.store.yahoo.com/mypiercing/c83-tmb17pf.html>. Last accessed March 15, 2004
11. Weinberg JB, Blackwood RA. Case report of *Staphylococcus aureus* endocarditis after navel piercing. *Pediatr Infect Dis J.* 2003;22:94-96
12. Cetta F, Graham LC, Lichtenberg RC, Warnes CA. Piercing and tattooing in patients with congenital heart disease: patient and physician perspectives. *J Adolesc Health.* 1999;24:160-162

Temporary Removal of Navel Piercing Jewelry for Surgery and Imaging Studies

Oliver J. Muensterer

Pediatrics 2004;114:384-386

DOI: 10.1542/peds.2004-0130

This information is current as of May 10, 2005

Updated Information & Services	including high-resolution figures, can be found at: http://www.pediatrics.org/cgi/content/full/114/3/e384
References	This article cites 10 articles, 1 of which you can access for free at: http://www.pediatrics.org/cgi/content/full/114/3/e384#BIBL
Post-Publication Peer Reviews (P³Rs)	2 P ³ Rs have been posted to this article: http://www.pediatrics.org/cgi/eletters/114/3/e384
Subspecialty Collections	This article, along with others on similar topics, appears in the following collection(s): Adolescent Medicine http://www.pediatrics.org/cgi/collection/adolescent_medicine
Permissions & Licensing	Information about reproducing this article in parts (figures, tables) or in its entirety can be found online at: http://www.pediatrics.org/misc/Permissions.shtml
Reprints	Information about ordering reprints can be found online: http://www.pediatrics.org/misc/reprints.shtml

American Academy of Pediatrics

DEDICATED TO THE HEALTH OF ALL CHILDREN™

