

Review

The significance of oral health in HIV disease

Iain L C Chapple, John Hamburger

The oral cavity is an important and frequently undervalued source of diagnostic and prognostic information in patients with HIV disease. A variety of conditions affecting oral mucosal tissues may arise either de novo or secondary to lesions elsewhere in the body and may provide the genitourinary physician with additional knowledge of individual patients' biological responses to their HIV infection. The mouth may also be a primary source of infection in any individual, which may spread via the mucosal associated lymphoid tissues or stimulate systemic inflammatory immune responses via chronic low grade entry of bacterially derived antigenic/virulence factors into the gingival vasculature.^{1,2} Indeed, the gingival and periodontal tissues are unique in structure, since they form the point at which internally linked hard tissues breach the epithelial surface rather like a compound bone fracture. This junction of tooth and gingiva provides a potentially weak barrier through which bacteria and their virulence factors (for example, lipopolysaccharide) may enter the connective tissues and systemic circulation (see fig 1). In this respect, maintaining a low microbial load within the mouth should be seen as an essential component of preventative treatment regimens in HIV positive patients.

When one considers that approximately 98% of lymphocytes reside in the tissues rather than

circulation, then the clinical condition of the oral mucosa and periodontal tissues may potentially provide valuable information, additional to viral load or CD4 counts, that may help in the management of HIV infected patients.

With the basic biology of both the oral mucosa and periodontal tissues in mind, the importance of oral lesions in HIV infection can be summarised as follows.

Oral lesions may:

- (1) Indicate HIV infection in previously undiagnosed cases³
- (2) Predict HIV disease progression⁴
- (3) Represent early clinical features of clinical AIDS (for example, oral Kaposi's sarcoma)⁵
- (4) Form traditional entry or exit determinants for antiretroviral therapy^{6,7}
- (5) Be determinants of anti-opportunistic infection therapy⁸
- (6) Be used in disease staging and classification⁵
- (7) Act as markers of other more subtle mucosal immunodeficiency states often missed on clinical examination⁹
- (8) Lead patients to seek treatment because of pain/discomfort or aesthetic reasons⁷
- (9) Individually correlate with CD4 levels in severely immunosuppressed patients¹⁰
- (10) Correlate with CD4 levels when grouped together (for CD4 counts $<200 \times 10^6/l$)⁴
- (11) Act as cofactors affecting the rate of HIV disease progression.

The oral lesions associated with HIV disease were classified by the EC Clearinghouse on Oral Problems Related to HIV Infection in 1991¹¹ and also by the US Workshop on Oral Manifestations in HIV Infection.¹² This system was revised in September 1992 by a joint working party from the former groups.¹³ Table 1 provides a classification of oral lesions with the designated grouping from that working party (I, II, or III) assigned as a superscript number. At the time, this was the most appropriate method of classification, but with hindsight it seems to be somewhat subjective rather than being necessarily evidence based. The literature now contains many epidemiological studies worldwide, and it would appear that the time for a further revision of this classification, based on the current evidence is approaching. The remainder of this review will deal briefly with some of the more common oral lesions. The references used in this review were those in the possession of the authors and the remainder were obtained using Medline.

Oral hairy leucoplakia

Oral hairy leucoplakia (OHL) was first described in 1984 by the Greenspans some 3

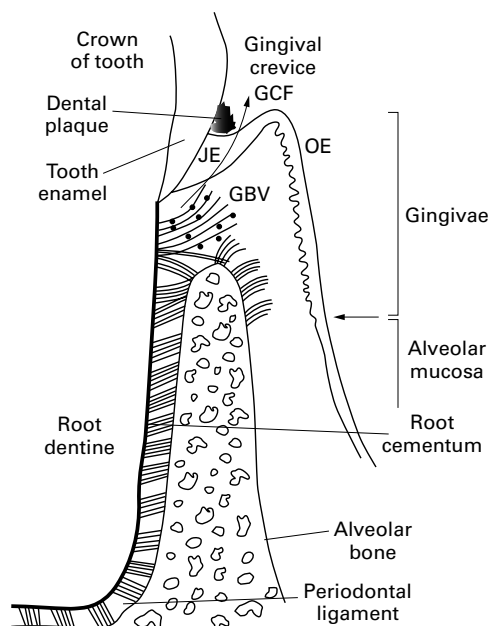


Figure 1 Schematic diagram of the tooth/gingival junction, demonstrating the permeable junctional epithelium, underlying connective tissues, and periodontal tissues. JE = junctional epithelium; OE = oral epithelium; GCF = gingival crevicular fluid; GBV = gingival blood vessels

Unit of Periodontology,
School of Dentistry,
University of
Birmingham, St
Chad's, Queensway,
Birmingham B4 6NN
I L C Chapple

Unit of Oral Medicine,
School of Dentistry
J Hamburger

Correspondence to:
Iain L C Chapple, School of
Dentistry, University of
Birmingham, St Chad's,
Queensway, Birmingham
B4 6NN

Accepted for publication
7 June 2000

Table 1 Oral lesions seen in HIV disease and their grouping according to the EC Clearinghouse on Oral Problems Related to HIV Infection, revised classification²²

| | |
|--|---|
| Neoplastic conditions | Viral infections |
| Kaposi's sarcoma ^I | Herpes simplex virus (HSV) ^{II} |
| Non-Hodgkin's lymphoma ^I | Primary herpes simplex I or II |
| | Recurrent oral herpes |
| | Herpes labialis (recurrent) |
| | Herpes zoster virus ^{II} |
| Bacterial infections | Cytomegalovirus (CMV) ulcers ^{III} |
| Periodontal infections | Hairy leucoplakia ^I |
| Acute necrotising ulcerative gingivitis (ANUG) ^I | Human papilloma virus (HPV) ^{II} |
| Linear gingival erythema (LGE) ^I | Condyloma acuminatum ^{II} |
| Acute necrotising ulcerative periodontitis (ANUP) ^I | Focal epithelial hyperplasia ^{II} |
| Acute necrotising stomatitis (ANS) ^{II} | Verruca vulgaris ^{II} |
| <i>Mycobacterium avium intracellulare</i> ^{II} | Molluscum contagiosum ^{III} |
| <i>Mycobacterium tuberculosis</i> ^{II} | |
| <i>Actinomyces israelii</i> ^{III} | Autoimmune disorders |
| <i>Escherichia coli</i> ^{III} | Recurrent aphthous ulcers ^{III} |
| <i>Klebsiella pneumoniae</i> ^{III} | HIV salivary gland disease ^{II} (DILS) |
| | Thrombocytopenic purpura ^{II} |
| Fungal infections | Neurological disturbances |
| Oral candidosis | Trigeminal neuralgia ^{III} |
| Pseudomembranous candidosis (thrush) ^I | Facial palsy (idiopathic) ^{III} |
| Erythematous candidosis ^I | Drug induced neuropathies |
| Chronic hyperplastic candidosis | |
| Angular cheilitis (<i>C. albicans</i> and staphylococci) | Other conditions |
| <i>Cryptococcus neoformans</i> ^{III} | Non-specific oral ulceration ^{II} |
| <i>Geotrichum candidum</i> ^{III} | Melanotic hyperpigmentation ^{II} |
| <i>Histoplasma capsulatum</i> ^{III} | Xerostomia (drug induced/other) |
| <i>Mucoraceae</i> ^{III} | Epithelioid angiomatosis ^I |
| <i>Aspergillus flavus</i> ^{III} | Cat scratch disease ^{III} |

I = group I "lesions strongly associated with HIV infection".

II = group II "lesions commonly associated with HIV infection".

III = group III "lesions associated with HIV infection".

years after it first came to their attention.¹⁴ Considerable research by this group and others has provided a body of evidence that the Epstein-Barr virus (EBV) is the likely cause of this lesion, which should probably now be renamed according to its aetiology as "EBV leucoplakia". While "presumptive" diagnosis of OHL can be made using clinical findings only,¹¹ it is desirable to identify EBV before assignment of such a diagnosis. Indeed, in one study the false positive diagnostic rate for presumptive criteria alone, when diagnoses were confirmed using both polymerase chain reaction (PCR) and in situ hybridisation was 17% for experienced oral physicians.¹⁵ The use of in situ PCR on EBV DNA enables diagnostic confirmation from individual cells, easily removed from the putative lesions for cytological examination. OHL was originally thought to be limited in presentation to homosexual males with HIV infection, but it does occur, although less commonly, in women,¹⁶ and rarely in children.

The incidence of OHL is reported to be 20% in CDC II individuals, increasing as CD4 counts fall and patients' clinical conditions deteriorate^{10,17}; it is thought to signal a more rapid progression to clinical AIDS.¹⁷ The pathogenesis of OHL is unclear and treatment is rarely indicated for this benign lesion, unless aesthetics are a concern. The lesion may temporarily disappear when patients commence antiretroviral therapy or indeed when they take high doses of aciclovir or ganciclovir,⁷ but its reappearance may indicate a decline in the effectiveness of HAART or may reflect a general worsening of a patient's clinical condition.

Kaposi's sarcoma

Kaposi's sarcoma (KS) is the most prevalent oral neoplasm in HIV infected patients, with

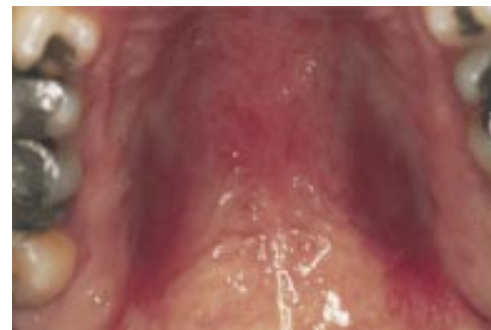


Figure 2 Bilateral KS lesions overlying the greater palatine vessels.

22% of KS lesions being present intraorally, 45% of patients presenting with both skin and oral lesions¹⁸ and the oral cavity being the first site of involvement in up to 60% of cases that present with multiple sites.¹⁹ The most common site for oral KS is the palate, followed by the gingival tissues. Gingival involvement may lead to underlying bone destruction and tooth mobility.³ Lesions may be macular or papulonodular, commonly light or dark red in colour though they may also have a blue colour and some are unpigmented.²⁰ They tend to be multicentric or symmetrical and the site of the lesion may indicate its likelihood of being a primary or secondary lesion. Palatal KS is recognised as being an important predictor of visceral lesions²¹ (fig 2). There is some evidence that oral KS lesions are associated with patients who have lower CD4 counts than those with skin lesions alone.²² Clinical diagnosis should be confirmed by histopathology since flat lesions can appear similar to erythroplakia, erythematous candidosis, thermal trauma, or a haematoma and nodular lesions may mimic pyogenic granulomata (PG), haemangioma, lymphoma, bacillary angiomatosis, or melanoma. Histological diagnosis has traditionally been difficult, particularly for early KS lesions, which may show none of the cellular atypia associated with vascular tumours.³ The discovery of the gamma herpes virus HHV8²³ and the potential for its oncogenic role in the aetiology of KS may lead to HHV8 serology playing an important part in the future for KS diagnosis.²⁴

Treatment of oral KS is directed towards control of spread and palliation, for aesthetic reasons, pain, or functional impairment. Various approaches have been employed including regional therapy using external beam radiotherapy or local therapy involving cytotoxic drugs such as vinblastine. Severe oral mucosal reactions were noted in 22% of 27 patients receiving 15 cGy, moderate reactions in 15%, and mild reactions in the remainder.²⁵ Modified schemes have thus been recommended with increasing numbers of fractions of 14–15 cGy doses.²⁶ Brachytherapy has also been used for more superficial lesions in an attempt to reduce the severe mucositis associated with external beam radiotherapy.²⁷

Other local therapy may involve excision of exophytic lesions or intralesional vinblastine. In 1993, Epstein reported 50% reduction in all

patients, and 75–100% reduction in 52% of patients in a trial using up to 3 ml of 0.2 mg/ml vinblastine.²⁸

Non-Hodgkin's lymphoma

Non-Hodgkin's lymphoma (NHL) is an uncommon feature of HIV disease. It is, however, the second most common malignancy in this condition, with 4% of AIDS patients developing NHL during the course of their disease. NHL of the oral cavity accounts for 3% of all malignant lymphomas in patients with HIV disease²⁹ and is an AIDS defining disease. Unlike classic malignant lymphoma, HIV associated tumours tend to occur extranodally.³⁰ Characteristically, oral tumours involve the fauces and gingivae but atypically may involve other sites such as the tongue.³¹ The clinical appearance varies but often presents as a rapidly enlarging mass with associated bony destruction. Occasionally, multifocal oral lesions occur and widespread disease is common at presentation. Lymphoma may be misdiagnosed as a Kaposi's sarcoma, particularly when it develops as a slow growing mass mimicking a vascular tumour.³² Other lesions may mimic dental sepsis or present as atypical oral ulceration⁷ and thus biopsy of lesions is mandatory to ensure appropriate management. Oral NHL appears not to be a feature of HIV infected children.³³ Histologically the tumours vary in nature but Levine reported the predominance of B cell lymphomas either of the immunoblastic or Burkitt's-like variants.³⁴ There is some evidence that large cell lymphoma is more common in patients with advanced HIV disease. Recently a new category of diffuse large B cell lymphoma, so called plasmablastic lymphoma, has been described in a series of 16 German patients, 15 of whom were HIV positive.³⁵ This entity predominantly arises within the oral cavity and typically involves the gingivae and palate.

The pathogenesis of NHL remains obscure but there has been much interest in the role of the Epstein–Barr virus with 50% of AIDS related tumours demonstrating EBV genomes and also in the possible aetiological role of HHV8.³⁶ Survival rates are low; Silverman quotes a 2 year survival rate of only 20%.³⁷

Oral candidosis

Oral candidosis may be the first presenting sign of HIV disease and is an important marker of its progression.³⁸ Samaranayake, in a meta-analysis, estimated the prevalence of oral candidosis in HIV disease as 33%–50%.³⁹ Other oral fungal infections such as histoplasmosis, cryptococcosis, geotrichosis, and aspergillosis may also be seen in patients with HIV infection, but much less frequently. Although oral candidosis is regarded as being associated with reducing CD4 counts,⁹ it may also occur very early in the course of the infection. There are several distinct variants of HIV associated oral candidosis. Pseudomembranous candidosis (thrush), presents as white/cream plaques easily removed from the underlying mucosa. It may occur at any intraoral site including the oropharynx. Angular cheilitis

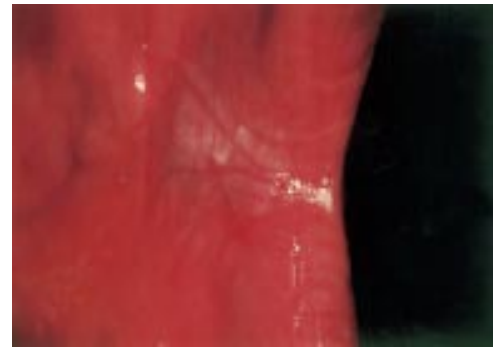


Figure 3 Chronic hyperplastic candidosis of the left buccal mucosa (this lesion is not removable by curettage).

presents at the anterior commissures as red, cracked, and fissured lesions, unilaterally or bilaterally, while chronic hyperplastic candidosis (fig 3) may also occur at this site although in HIV disease, it tends to occur more buccally. Classically, chronic hyperplastic candidosis appears as a white or a red and white speckled lesion that is adherent. It also has malignant potential. Erythematous candidosis is normally associated with the wearing of dentures, broad spectrum antibiotics, or corticosteroid therapy in the general population. In HIV infection, it presents on the dorsum of the tongue and palatal mucosa, as an area of erythema that may also contain pseudomembranous candidosis. Of the four variants described, acute pseudomembranous and erythematous candidosis are the most prevalent, occurring in 20–25% of patients with HIV infection.⁴⁰

The pathogenesis of HIV associated oral candidosis may involve increased adhesiveness, the ability to invade mucosal surfaces encouraged by hyphal formation, thigmotropism and protease secretion, acquisition of virulent strains, and phenotypic switching.⁴¹ *Candida albicans* is the most common intraoral species but other species including *C. tropicalis*, *C. glabrata*, and *C. krusei* have also been isolated.⁴⁰ More recently a newly identified species, phenotypically similar to *C. albicans*, and known as *C. dubliniensis*, has been described in HIV associated oral candidosis, but its role in HIV infection remains obscure.

The management of oral candidosis includes the use of topical polyenes and systemic imidazoles and triazoles. The mainstay of therapy has been fluconazole but its therapeutic value has been compromised by the emergence of fungal resistance to the drug which is most commonly observed in association with low CD4 counts⁷ and progression of HIV disease.

Herpes simplex virus

Herpes simplex virus (HSV) 1 and 2 can arise in the mouth as primary infections or recurrent lesions. HSV-1 is ubiquitous, most humans being exposed at an early age via parental saliva. The primary infection classically appears as small vesicles, which may affect any oral mucosal surface, but predominantly affects the keratinised tissues of the hard palate and gingivae. The vesicles are associated with fever and cervical lymphadenopathy, and rupture leads to the formation of small circular

ulcers, which are painful. The ulcers can coalesce to form larger serpiginous lesions and there may be an angry erythematous inflammation of the gingivae. Primary HSV infection is relatively uncommon in HIV infected adolescents and adults owing to the high prevalence of antibody to HSV (seropositivity is 90–95% in homosexual men and injecting drug users). Clinical diagnosis may be confirmed with cytology and direct immunofluorescence, rather than viral culture.⁴² However, electron microscopy and PCR now provide greater sensitivity as diagnostic tools. Reactivation of HSV from latent virus residing in the trigeminal (HSV-1) or sacral (HSV-2) ganglia can lead to regionalised lesions or more widespread chronic mucocutaneous disease. In recurrent oral herpes in HIV positive individuals the ulceration is again shallow and widespread affecting the buccal mucosa, tongue, and lips where there may be crusting and bleeding similar in appearance to erythema multiforme. The incidence of HSV-1 and 2 oral ulceration is reported to be between 0.6–9% in HIV positive patients and lesions can be more severe and prolonged.⁴³ There have been recent reports of oral ulcers co-infected by HSV-1 and 2 and CMV,⁴⁴ though the pathogenesis of such lesions remains unknown. Typical treatment regimens include oral aciclovir 400 mg, five times daily for 5 days, or in more severe infections (lesions that persist for more than 1 month) 5 mg/kg by intravenous infusion three times daily for a minimum of 5 days. In cases of aciclovir resistance, foscarnet 40–60 mg/kg three times daily is recommended.

Recurrent oral varicella zoster virus (VZV) infections again arise from the trigeminal ganglion, are associated with a prodrome and affect one or more branches of the trigeminal nerve. Infections seem to be more severe and prolonged in HIV positive patients and are reported to have an incidence seven times greater than in the general population.⁴⁵ Treatment involves aciclovir 30 mg/kg daily although resistance has been reported.⁴⁶

Oral ulceration

Oral ulceration of varying aetiologies is common within the general population, with 20% of individuals experiencing recurrent aphthae. This is also a feature of HIV disease, often producing significant morbidity in these patients. McPhail and Greenspan reported that 31% of patients presenting with HIV associated oral problems had oral ulceration.⁴⁷ The aetiology of HIV associated oral ulceration is multifactorial and can be classified as: infective (fungal, bacterial, viral, and protozoal); neoplastic (lymphoma and squamous cell carcinoma); aphthous; ulceration not otherwise specified (NOS, non-infective nor neoplastic ulcerations which may have similar features to aphthae and have non-specific histology); iatrogenic. Of these categories, viral and aphthous ulcers predominate.

Herpes simplex has previously been considered. Oral ulceration as a result of CMV is rare, but when it occurs, it has a predilection for

palatal and gingival mucosa and appears as punched out ulceration lacking an erythematous halo (normally characteristic of aphthae).

Aphthous ulceration and NOS will be considered together as there is some debate as to whether these entities are indeed truly discrete. HIV associated aphthae tend to be more severe in terms of their number, frequency, pain, and duration than for the general population. Serum B12 and folate deficiency are predisposing factors for aphthae and while such deficiencies are not uncommon in HIV disease, HIV associated oral ulceration has been proposed to be independent of these factors.⁴⁷ Severe major aphthae may suggest CD4 counts less than 100 cells $\times 10^6/l$ and thus may signal disease progression.³³ Concurrent involvement of the oral and oesophageal mucosa may result in dysphagia.

Iatrogenic ulceration may result from the use of a variety of drugs including foscarnet and interferon,⁴⁸ while secondary effects of drug therapy, such as zidovudine induced agranulocytosis⁴⁹ or as a consequence of the use of cytotoxics, may also cause oral ulceration. Stevens–Johnson syndrome and toxic epidermolysis have also been reported following the administration of ketoconazole and sulphonamides.⁵⁰ Non-ulcerative drug induced problems will be discussed briefly later.

Neoplastic ulceration is uncommon but may reflect NHL or squamous cell carcinoma.⁵¹ Atypical KS may also present with ulceration. It is still uncertain as to whether squamous cell carcinoma is more prevalent in HIV disease; however, it does appear to target a younger population in the absence of the usual risk factors.⁵²

Ulceration due to mycotic, bacterial, and protozoal causes is rare. Ficarra described ulceration in angular cheilitis,⁵³ while ulcers have also been described in oral cryptococcosis⁵⁴ and histoplasmosis.⁵⁵ Bacillary epithelioid angiomatosis due to *Rochalimaea henselae* is associated with oral ulceration. Oral ulceration may also be a consequence of infection with syphilis or *Mycobacterium avium intracellulare*.⁵⁶

Treatment for recurrent oral ulceration varies from topical steroid agents to thalidomide.⁵⁷

The human periodontal diseases

The human periodontal diseases are those diseases affecting the supporting structures of the teeth—that is, the gingivae, periodontal ligament, root cementum, and alveolar bone (see fig 1). They have been poorly researched in HIV disease until recently, with anecdotal reports fuelling speculation that they represent a far more significant problem in HIV patients than current evidence now suggests. There are many conditions that affect these tissues, the majority being manifestations of systemic diseases, but five types are specifically associated with the HIV positive patient. They are:

- Linear gingival erythema (LGE)
- Acute necrotising ulcerative gingivitis (ANUG) or necrotising ulcerative gingivitis (NUG)

- Acute necrotising ulcerative periodontitis (ANUP) or necrotising ulcerative periodontitis (NUP)
- Acute necrotising stomatitis (ANS) or necrotising ulcerative stomatitis (NUS)
- Chronic adult periodontitis (CAP).

LGE is a clinical term that describes the appearance of the gingival tissues, rather than representing a true diagnosis. The condition is poorly understood, and the clinical criteria used to define it vary from one study to the next. It is characterised by a broad 2–3 mm fiery red band along the margin of the gingival tissues and diffuse or petechial-like lesions from the attached gingivae and oral mucosa. There is accumulating evidence for candidal involvement in the aetiology of a majority of such lesions. One study of 77 seropositive and 44 seronegative homosexual males, along with 39 seronegative injecting drug users (IDUs), demonstrated a significant relation between LGE and oral candidosis and a trend towards increasing LGE with decreasing CD4 counts. Further analysis of drug histories demonstrated that 85% of subjects who presented with LGE either had oral candidosis or had recently taken a course of antifungal therapy.⁵⁸ The evidence to date would suggest that “LGE” represents an unusual manifestation of, or tissue response to, fungal agents in immunosuppressed patients and that oral candidosis, neutropenia, herpes family viral infections, and plaque induced erythema should all be suspected as aetiological agents.

ANUG or NUG are essentially the same condition. In NUG the underlying immunosuppression is HIV induced, whereas in “traditional” ANUG the immunosuppression may be induced by stress or poor diet. Smoking in subjects with poor oral hygiene also contributes to both. ANUG is a fusospirochaetal infection involving *Treponema vincentii* and *Fusobacterium nucleatum* (which invade the gingival tissues), with reports of involvement by *Prevotella intermedia* and *Candida* sp. It causes very painful, necrotic, and sloughing ulcers of the tips of interdental papillae, which spread along the marginal gingivae to cause widespread necrosis of the soft tissues only. Since gingival pain is very rare, its occurrence alongside ulceration of the papillae tips is pathognomonic of ANUG. One recent study of gingival ulceration indicated an incidence of 6.8% in 1308 patients presenting with gingival ulceration consistent with ANUG.⁵⁹ Treatment involves local debridement supplemented with metronidazole 200–400 mg three times daily for 3 days.

ANUP or NUP (fig 4, formerly HIV periodontitis) is believed to represent a deeper seated and more chronic form of ANUG, spreading to cause destruction of periodontal ligament and loss of adjacent alveolar bone. It is a more serious condition than ANUG and indicates greater immunosuppression. The prevalence of ANUP has been reported as 6.3%.⁶⁰ Specialist treatment is necessary and involves the use of metronidazole in conjunction with root surface debridement under a local anaesthetic.

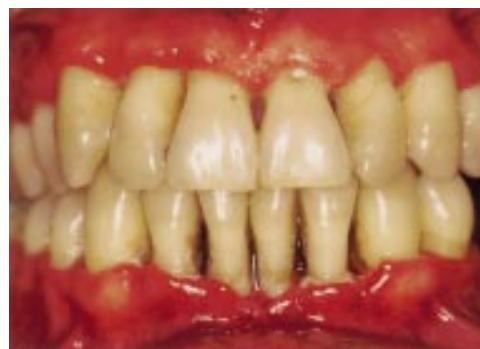

Figure 4 Acute necrotising periodontitis; note the grey slough at the gingival margin of the lower incisor teeth and the loss of attachment that has caused gingival recession.

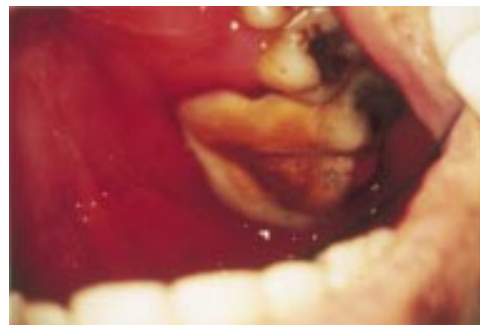


Figure 5 Acute necrotising stomatitis affecting the upper left maxillary quadrant. The tissues beneath are necrotic. This patient survived without difficulty in eating and with no pain for 18 months before dying from PCP.

ANS is believed to be a further progression of ANUP to form an ulcerative lesion that extends more than 10 mm beyond the gingival margin. Its behaviour is aggressive leading to necrosis of underlying bone and loss of tooth vitality (see fig 5). There have been reports of oro-nasal fistulae developing.⁶¹ If the patient is well enough to receive a general anaesthetic without anaesthetic complications, then broad excision of the involved area of bone (usually maxilla) back to healthy bleeding bone margins is recommended, followed by surgical packing of the defect to allow gradual healing by secondary intention. If the patient is a poor anaesthetic or surgical risk, then conservative management is more appropriate.

CAP affects approximately 69% of all adults (having early signs of disease) and only 5% are completely free from clinical signs of inflammation.⁶² Significant attachment loss is reported in around 5–10% of most populations. There are conflicting reports as to whether or not the incidence and rates of progression in this complex disease are the same or higher in HIV positive individuals compared with HIV negative subjects. It has long been recognised that the destruction measured at presentation can often be historical disease that is no longer active, and may have occurred before HIV infection. Cross sectional studies are thus of limited value in answering these questions. Smith *et al.*,^{63 64} assessed disease progression and microbiological and immunological markers. They found no difference in baseline attachment loss between HIV positive and negative individuals, and disease progressed at only 1% of sites over the monitoring period.

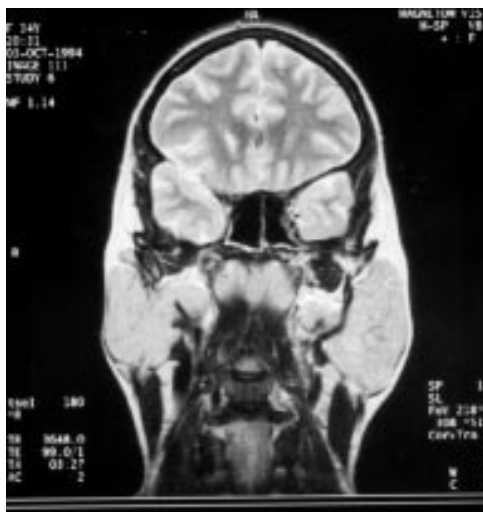

Figure 6 Magnetic resonance imaging scan showing enlarged parotid glands in a female with HIV salivary gland disease. Radioisotopic scans revealed negligible glandular function.

Their microbiological findings showed very similar subgingival flora in test and control groups. However, their HIV positive group was small (n=29). Mild CAP in HIV positive patients can be easily managed in general dental practice, but more advanced disease may require specialist referral.

HIV associated salivary gland disease

HIV associated salivary gland disease covers a variety of pathologies that can affect the salivary glands in HIV disease but the usual manifestations are diffuse enlargement of the major salivary glands (fig 6) or xerostomia, which may occur concurrently. Although the salivary gland swelling is usually non-neoplastic, KS⁶⁵ and lymphoma⁶⁶ have been reported involving the parotid glands. Of the non-neoplastic lesions, these essentially comprise cystic changes, Sjogren's-like disease, and lymphoid infiltration. Many entities have been described but it is likely that a number of these overlap and are not truly separate pathologies. However, cystic lesions in parotid salivary glands were regarded as a rare finding before the advent of HIV disease and are thought to represent a new phenomenon.⁶⁷ The lymphoid infiltration that occurs in some patients is known as "diffuse infiltrative lymphocytosis syndrome" (DILS). It shares a number of clinical features with Sjogren's syndrome.⁶⁸ However, it differs in that the predominant infiltrating cells are CD8 positive T cells and not CD4 as in "true" Sjogren's syndrome. Furthermore, the typical autoantibody profile seen in Sjogren's syndrome is not a feature of DILS.⁶⁹ DILS may be a favourable prognostic marker in HIV disease, such patients experiencing a slower rate of disease progression,⁷⁰ possibly as a result of the infiltrating cells being cytotoxic to the HIV virion.

The onset of salivary gland involvement appears to be independent of the stage of the HIV infection and the degree of immunodeficiency. However, patients may have associ-

ated extraglandular comorbidity including lymphoid interstitial pneumonitis, gastritis, and hepatitis.⁶⁸

HIV associated salivary gland disease is seen most commonly in children, up to 58% of them developing salivary gland enlargement⁷⁰ and is uncommon in HIV infected adults. The pathogenesis of HIV associated salivary gland disease remains obscure.

As a result of the varied pathology of HIV associated salivary gland disease, but similar presenting features, careful investigation is mandatory to ensure accurate diagnosis. Plain radiography, computed tomography, and magnetic resonance imaging as well as open biopsy all have a part to play.

Drug induced oral lesions in HIV disease

As well as drug induced oral ulceration discussed previously, other oral conditions may also be provoked by the diverse medication used in the management of patients with HIV disease. These include lichenoid reactions, xerostomia (didanosine, indinavir), mucosal pigmentation (zidovudine), and taste disturbances (indinavir).⁷¹ A more detailed review of drug induced lesions is provided by Porter and Scully.⁷²

The impact of HAART on oral lesions

The introduction of highly active antiretroviral therapy (HAART) appears to have reduced the incidence of HIV associated oral lesions. However, there is currently little objective prospective data to support this clinical impression, with the exception of oral candidosis, which was found to be virtually eliminated in one study of HAART medicated subjects.⁷³

The protective role of the mouth

The protective role of the mouth against HIV transmission was initially investigated owing to the rarity of HIV infection via the oral route,⁷⁴ and is thought to be due to a variety of endogenous inhibitors present within saliva. In addition, the oral mucosa is generally much thicker than vaginal or rectal mucosa, and Langerhans cells are generally deep within the epithelium. Nevertheless, the oral barrier is broken when ulcers form, during gingival/periodontal diseases or with trauma, providing open lesions through which virus may pass. Shugars *et al*⁷⁴ reviewed endogenous salivary mechanisms and tabulated 14, including high molecular weight mucins which may bind the HIV-1 virus making it insoluble,⁷⁵ and HIV specific antibodies which may inactivate the virus. Perhaps the most interesting is secretory leucocyte protease inhibitor (SLPI) defined in 1986⁷⁶ as a protein active against neutrophil proteases and secreted by non-ciliated epithelial cells of mucosal surfaces. Recently, the inhibitory activity of SLPI against HIV-1 infection of monocytes has been demonstrated in a number of reports⁷⁷ and appears to be effective only during viral infection of such target monocytes. It does not block initial interaction of the virus and CD4 receptors, or affect reverse transcription, virus assembly, or budding⁷⁷ and seems to function between CD4 binding and reverse transcrip-

tion. The activity of SLPI and other endogenous salivary inhibitors of HIV appear to afford protection against infection, despite reports of recovery of viral RNA and proviral DNA from saliva.⁷⁴

The mouth can be easily examined by clinicians and the simplicity of diagnosing some oral lesions using direct clinical findings alone is supported by the recognition that such oral lesions can be diagnosed on "presumptive" clinical criteria alone.¹¹ By contrast, other oral lesions have very subtle appearances and may be misdiagnosed by the inexperienced eye. In one study of primary care physicians only 26% were able to identify and correctly diagnose oral KS lesions and 22% lesions of hairy leukoplakia,⁷⁸ while in a second study, dental examiners were significantly more successful in identifying oral lesions in HIV disease.⁷⁹ Such findings indicate the importance of adopting a team approach involving physicians, dental surgeons, nursing staff, and community care workers, with the genitourinary physicians taking the lead in management and coordination of services. It has been demonstrated that the physicians' experience with AIDS and HIV has a significant bearing on patient survival,⁸⁰ and such a holistic approach to care can only improve clinical outcomes.

Referral guidelines

The decision to refer HIV positive patients for oral care clearly depends on the experience of the referring practitioner. Lesions that are of dental origin—that is, those involving the teeth and adjacent alveolus, are best managed initially by the general dental practitioner (GDP). Most dental pain relates to dental caries or pulpal inflammation and should be treated in the primary care setting. Gingival pain is an unusual sign and often relates to ulcerative gingival or periodontal conditions. Referral to a specialist in periodontology or restorative dentistry is the most appropriate way of dealing with such lesions, whereas gingival inflammation (bleeding on brushing or redness and swelling of gingivae) or CAP should initially be managed by the patient's GDP, who may or may not refer for secondary care. Oral mucosal and salivary gland disease are best managed jointly by oral and genitourinary physicians.

- 1 Shapira L, Soskolne WA, Sela MN, *et al.* The secretion of PGE₂, IL-1-β, IL-6 and TNF-α by monocytes from early onset periodontitis patients. *J Periodontol* 1994;65:139–46.
- 2 Beck J, Garcia R, Heiss G, *et al.* Periodontal disease and cardiovascular disease. *J Periodontol* 1996;67:1123–37.
- 3 Chapple ILC, Rout PJ, Basu MK. Gingival Kaposi's sarcoma: the first indication of HIV infection. *Dental Update* 1992;19:296–301.
- 4 Begg MD, Lamster IB, Panageas KS, *et al.* A prospective study of oral lesions and their predictive value for progression of HIV disease. *Oral Diseases* 1997;3:176–83.
- 5 Centres for Disease Control and Prevention. 1993 revised classification system for HIV infection and expanded surveillance case definition for AIDS among adolescents and adults. *MMWR* 1993;41:1–19.
- 6 Greenspan JS. Sentinels and signposts: the epidemiology and significance of the oral manifestations of HIV disease. *Oral Diseases* 1997;3:S13–17.
- 7 Greenspan JS, Greenspan D. HIV-related oral disease. *Lancet* 1996;348:729–33.
- 8 Carpenter CCJ, Fischl MA, Hammer SM, *et al.* Antiretroviral therapy for HIV infection in 1996. *JAMA* 1996;276:146–54.

- 9 Nielson H, Bensten KD, Hojtvad L, *et al.* Oral candidosis and immune status of HIV-infected patients. *J Oral Pathol Med* 1994;23:140–3.
- 10 Glick M, Muzyka BC, Lurie D, *et al.* Oral manifestations associated with HIV-related disease as markers for immune suppression and AIDS. *Oral Surg, Oral Med, Oral Pathol* 1994;77:344–9.
- 11 EC Clearinghouse on Oral Problems Related to HIV Infection and WHO Collaborating Centre on Oral manifestations of the Immunodeficiency Virus. An update of the classification and diagnostic criteria of oral lesions in HIV infection. *J Oral Pathol Med* 1991;20:97–100.
- 12 Greenspan JS, Barr CE, Sciubba JJ, *et al.* Oral manifestations of HIV infection: definitions, diagnostic criteria and principles of therapy. *Oral Surg, Oral Med, Oral Pathol* 1992;73:142–4.
- 13 EC Clearinghouse on Oral Problems Related to HIV Infection and WHO Collaborating Centre on Oral manifestations of the Immunodeficiency Virus. Classification and diagnostic criteria for oral lesions in HIV infection. *J Oral Pathol Med* 1993;22:289–91.
- 14 Greenspan D, Greenspan JS, Conant M, *et al.* Oral "hairy" leukoplakia in male homosexuals: evidence of association with papillomavirus and a herpes-group virus. *Lancet* 1984;ii:831–4.
- 15 Felix DH, Jalal H, Cubie HA, *et al.* Detection of Epstein-Barr virus and human papillomavirus type 16 DNA in hairy leukoplakia by in-situ hybridisation and the polymerase chain reaction. *J Oral Pathol Med* 1993;22:277–81.
- 16 Shiboski CH. Epidemiology of HIV-related oral manifestations in women: a review. *Oral Diseases* 1997;3:S18–27.
- 17 Lifson AR, Hilton JF, Westenhouse JL, *et al.* Time from HIV seroconversion to oral candidosis or hairy leukoplakia among homosexual and bisexual men enrolled in three prospective cohorts. *AIDS* 1994;8:73–9.
- 18 Tappero JW, Conant MA, Wolfe SF, *et al.* Kaposi's sarcoma. *J Am Acad Dermatol* 1993;28:371–95.
- 19 Ficarra G, Eversole LE. HIV-related tumours of the oral cavity. *Crit Rev Oral Biol Med* 1994;5:159–85.
- 20 Daly CG, Allan BP, Bhagwande SB, *et al.* Kaposi's sarcoma of the palate in a patient with AIDS: an unusual presentation. *Aust Dent J* 1988;34:101–5.
- 21 Miller RF, Tomlinson MC, Cottrill CP, *et al.* Bronchopulmonary Kaposi's sarcoma in patients with AIDS. *Thorax* 1992;47:721–5.
- 22 Orfanos CE, Husak R, Wolfer U, *et al.* Kaposi's sarcoma: a re-evaluation. Recent results. *Cancer Res* 1995;139:275–96.
- 23 Chang Y, Cesarman E, Pessin MS, *et al.* Identification of herpesvirus-like DNA sequences in AIDS-associated Kaposi's sarcoma. *Science* 1994;266:1865–9.
- 24 Moore PS, Gao SJ, Dominguez G, *et al.* Primary characterization of a herpesvirus agent associated with Kaposi's sarcoma. *J Virol* 1996;70:549–58.
- 25 LeBourgeois JP, Frikha H, Piedbois P, *et al.* Radiotherapy in the management of epidemic Kaposi's sarcoma of the oral cavity, the eyelid and the genitals. *Radiother Oncol* 1994;30:263–6.
- 26 Piedbois P, Frikha H, Martin L, *et al.* Radiotherapy in the management of epidemic Kaposi's sarcoma. *Int J Radiat Oncol Biol Phys* 1994;30:1207–11.
- 27 Evans MD, Yassa M, Podgorsak EB, *et al.* Surface applicators for high dose rate brachytherapy in AIDS-related Kaposi's sarcoma. *Int J Radiat Oncol Biol Phys* 1997;39:769–74.
- 28 Epstein JB. Treatment of oral Kaposi's sarcoma with intralosomal vinblastine. *Cancer* 1993;71:1722–5.
- 29 Epstein JB, Silverman S Jr. Head and neck malignancies associated with HIV infection. *Oral Surg, Oral Med, Oral Pathol* 1992;73:193–300.
- 30 Beral V. Epidemiology of cancer in AIDS patients. *AIDS* 1991;5:S99–103.
- 31 Boring CC, Brynes RK, Chan WC, *et al.* Increase in high grade lymphomas in young men. *Lancet* 1985;1:857–9.
- 32 Piluso S, Di Lollo S, Baroni G, *et al.* Unusual clinical aspects of oral non-Hodgkin's lymphomas in patients with HIV infection. *Oral Oncol, Eur J Cancer* 1994;30B:61–4.
- 33 Ramos-Gomez FJ. Oral aspects of HIV disease in children. *Oral Diseases* 1997;3(Suppl 1):S31–5.
- 34 Levine AM. Acquired immunodeficiency syndrome-related lymphoma. *Blood* 1992;80:8–20.
- 35 Delecluse HJ, Anagnostopoulos I, Dallenback F, *et al.* Plasmablastic lymphomas of the oral cavity: a new entity associated with the human immunodeficiency virus infection. *Blood* 1997;89:1413–14.
- 36 Boshoff C, Whitby D, Talbot S, *et al.* Aetiology of AIDS-related Kaposi's sarcoma and lymphoma. *Oral Diseases* 1997;3(Suppl 1):S129–32.
- 37 Silverman S Jr. *Colour atlas of oral manifestations of AIDS*. 2nd ed. St Louis: Mosby, 1996:101–4.
- 38 Klein RS, Harris CA, Small CB, *et al.* Oral candidiasis in high risk patients as the initial manifestation of the acquired immunodeficiency syndrome. *N Engl J Med* 1984;311:354–57.
- 39 Samaranayake LP. Oral mycoses in HIV infection. *Oral Surg, Oral Med, Oral Pathol* 1992;73:171–80.
- 40 Korting HC, Ollert M, Georgii A, *et al.* In vitro susceptibilities and biotypes of *Candida albicans* isolates from the oral cavities of patients with human immunodeficiency virus. *J Clin Microbiol* 1989;26:2626–31.
- 41 Samaranayake LP. Oral candidosis: predisposing factors and pathogenesis. In: Derrick DD, ed. *Dental annual 1989*. Bristol: Wright, 1989:219–35.

- 42 MacPhail L, Hilton J, Heinic G, *et al.* Direct immunofluorescence vs culture for detecting HSV in oral ulcers: a comparison. *JADA* 1995;126:74-8.
- 43 Reichart PA. Oral ulcerations in HIV infection. *Oral Diseases* 1997;3:S180-2.
- 44 Regezi J, Eversole R, Barker B, *et al.* Herpes simplex and cytomegalovirus co-infected oral ulcers in HIV-positive patients. *Oral Surg, Oral Med, Oral Pathol, Oral Radiol* 1996;81:55-62.
- 45 Eversole L. Viral infections of the head and neck upon HIV-seropositive patients. *Oral Surg, Oral Med, Oral Pathol* 1992;73:155-63.
- 46 Jacobson M, Berger T, Fikrig S, *et al.* Acyclovir resistant varicella zoster virus infection after chronic oral acyclovir therapy in patients with the acquired immunodeficiency syndrome (AIDS). *Ann Intern Med* 1992;112:187-91.
- 47 MacPhail LA, Greenspan JS. Oral ulceration in HIV infection: investigation and pathogenesis. *Oral Diseases* 1997;3(Suppl 1):S190-3.
- 48 Gilquin J, Wiss L, Kazatchkine MD, *et al.* Genital and oral erosions induced by foscarnet. *Lancet* 1990;335:287.
- 49 Reichert P. Oral ulceration and iatrogenic disease in HIV infection. *Oral Surg, Oral Med, Oral Pathol* 1992;73:212-14.
- 50 Rzyany B, Mockenhaupt M, Stocker U, *et al.* Incidence of Stevens-Johnson syndrome and toxic epidermal necrolysis in patients with acquired immunodeficiency syndrome in Germany. *Arch Dermatol* 1993;129:1059-64.
- 51 Flaitz CM, Nichols CM, Adler-Stothz K, *et al.* Intraoral squamous cell carcinoma in HIV infection: a clinicopathological study. *Oral Surg, Oral Med, Oral Pathol* 1995;80:55-62.
- 52 Ficarra G, Eversole R. HIV-related tumours of the oral cavity. *Crit Rev Oral Biol Med* 1994;5:159-85.
- 53 Ficarra G. Oral ulcerations in patients with HIV infection: aetiology, diagnosis and management. In: Greenspan JS, Greenspan D eds. *Proceedings of the II International Workshop on Oral Manifestations of HIV Infection*. Chicago: Quintessence Publishing Co, 1995:205-17.
- 54 Schmidt-Westhausen A, Grunewald TH, Reichart PA, *et al.* Oral cryptococcosis in a patient with AIDS. A case report. *Oral Dis* 1995;1:77-9.
- 55 Swindells S, Durham T, Johansson SL, *et al.* Oral histoplasmosis in a patient infected with HIV. A case report. *Oral Surg, Oral Med, Oral Pathol* 1994;77:126-30.
- 56 Robinson P, Farthing P, Scott GM, *et al.* Oral Mycobacterium avium complex infection in a patient with HIV-related disease. A case report. *Oral Surg, Oral Med, Oral Pathol* 1996;81:177-9.
- 57 Ghigliotti G, Repetto T, Farris A, *et al.* Thalidomide for severe aphthous ulceration in patients with HIV infection. *J Am Acad Dermatol* 1993;28:271-2.
- 58 Grbic JT, Mitchell-Lewis DA, Fine JB, *et al.* The relationship of candidosis to linear gingival erythema in HIV-infected homosexual men and parenteral drug users. *J Periodontol* 1995;66:30-7.
- 59 Robinson PG, Sheiham A, Challacombe SJ, *et al.* Gingival ulceration in HIV infection. A case series and case control study. *J Periodontol* 1998;25:260-7.
- 60 Glick M, Muzyka BC, Slakin LM, *et al.* Necrotizing ulcerative periodontitis: a marker for immune deterioration and a predictor for the diagnosis of AIDS. *J Periodontol* 1994;65:393-7.
- 61 Felix DH, Wray D, Smith GLF, *et al.* Oral-antral fistula: an unusual complication of HIV-associated periodontal disease. *Br Dent J* 1991;171:61-2.
- 62 Todd JE, Lader D. 1988 *Adult dental health survey of the United Kingdom*. London: Office of Population Censuses and Surveys, Social Division, 1991:131-44.
- 63 Smith GLF, Cross DL, Wray D. Comparison of periodontal disease in HIV seropositive subjects and controls (I). Clinical features. *J Clin Periodontol* 1995;22:558-68.
- 64 Cross DL, Smith GLF. Comparison of periodontal disease in HIV seropositive subjects and controls (II). Microbiology, immunology and predictors of disease progression. *J Clin Periodontol* 1995;22:569-77.
- 65 Yeh C-K, Fox PC, Travis WD, *et al.* Kaposi's sarcoma of the parotid gland in acquired immunodeficiency syndrome. *Oral Surg, Oral Med, Oral Pathol* 1989;67:308-12.
- 66 Joachim HL, Ryan JR, Blaugrand SM. Salivary gland lymph nodes: the site of lymphadenopathies and lymphomas associated with human immunodeficiency virus infection. *Arch Pathol Lab Med* 1988;112:1224-8.
- 67 Shugar JMA, Som PM, Jacobsen AL, *et al.* Multicentric parotid cysts and cervical adenopathy in AIDS patients: a newly recognised entity—CT and MR manifestations. *Laryngoscope* 1988;20:355-7.
- 68 Itescu S, Winchester R. Diffuse infiltrative lymphocytosis syndrome: a disorder occurring in human immunodeficiency virus-1 infection that may present as a sicca syndrome. *Rheum Dis N Am* 1990;118:683-97.
- 69 Schiodt M, Greenspan D, Daniels TE, *et al.* Parotid gland enlargement and xerostomia associated with labial sialadenitis in HIV-infected patients. *J Autoimmun* 1989;2:415-25.
- 70 Katz MH, Mastrucci MT, Leggott PJ, *et al.* Prognostic significance of oral lesions in children with perinatally acquired human immunodeficiency virus syndrome. *Am J Dis Child* 1993;147:45-8.
- 71 Schiodt M. Less common oral lesions associated with HIV infection: prevalence and classification. *Oral Diseases* 1997;3(Suppl 1):S208-213.
- 72 Porter SR, Scully C. HIV topic update: protease inhibitor therapy and oral health care. *Oral Diseases* 1998;4:159-63.
- 73 Cauda R, Tacconelli E, Tumbarello M, *et al.* Role of protease inhibitors in preventing recurrent oral candidosis in patients with HIV infection: a prospective case-control study. *J Acquir Immun Defic Syndr* 1999;21:20-5.
- 74 Shugars DC, Alexander AL, Fu K, *et al.* Endogenous salivary inhibitors of human immunodeficiency virus. *Arch Oral Biol* 1999;44:445-53.
- 75 Malamud D, Davis C, Berthold P, *et al.* Human submandibular saliva aggregates HIV. *AIDS Res Hum Retrovir* 1993;9:633-7.
- 76 Thompson RC, Ohlsson K. Isolation, properties and complete amino acid sequences of human secretory leukocyte protease inhibitor, a potent inhibitor of leukocyte elastase. *Proc Natl Acad Sci USA* 1986;83:6692-6.
- 77 Shugars DC, Sauls DL, Weinberg JB. Secretory leukocyte protease inhibitor blocks infectivity of primary monocytes and mononuclear cells with both monocytotropic and lymphocytotropic strains of human immunodeficiency virus type 1. *Oral Diseases* 1997;3:S70-2.
- 78 Cruz G, Lamster I, Begg MD, *et al.* The accurate diagnosis of oral lesions in HIV infection: impact on medical staging. *Arch Otolaryng Head Neck Surg* 1996;122:68-73.
- 79 Paauw DS, Wenrich MD, Curtis R, *et al.* Ability of primary care physicians to recognise physical findings associated with HIV infection. *JAMA* 1995;274:1380-2.
- 80 Kitahata MM, Koepsell TD, Deyo RA, *et al.* Physicians' experience with the acquired immunodeficiency syndrome as a factor in patients' survival. *N Engl J Med* 1996;334:701-6.