

Tongue piercing resulting in hypotensive collapse

P. S. G. F. Hardee,¹ L. R. Mallya,² and I. L. Hutchison,³

Tongue piercing remains popular. A variety of complications have been reported, including life-threatening infection, airway problems and damaged teeth or mucosal surfaces. A patient who collapsed after continuous profuse bleeding following tongue piercing is presented. It is recommended that piercing practitioners be licensed and inspected. A list of written post piercing instructions for customers is included on how to deal with, or who to contact regarding potential complications including haemorrhage.

Body piercing is an ancient practice.¹ Oral piercing appears to be a more recent practice in Western society, with the first report in the medical literature appearing in 1992.² The first report of a potentially life-threatening complication appeared some years later,³ and involved spreading infection resulting in Ludwig's angina and airway compromise. We report on a patient who collapsed in hypotensive shock secondary to tongue piercing.

Case report

An otherwise fit and well 19-year-old girl collapsed in her mother's car about 4 hours after having her tongue pierced and a barbell placed. She had had her tongue pierced at a tattooist specialising in body piercing, (encouraged by her friends many of whom had tongue, lip, nose or eyebrow piercings at the same establishment).

Her post-operative instructions, given verbally, were:

- Rinse out after food, drinking or smoking
- Do not eat hot or solid food
- Suck ice cubes to reduce swelling.

She was not given any instructions on control of bleeding. She noticed continuous (but not pulsatile) bleeding from the moment of piercing. By the time she reached home (1 hour later) she was spit-

In brief

- Tongue piercing is potentially dangerous
- Body piercing studios should be inspected and licensed
- Body piercing studios should give clients written advice on risks, and post-piercing care

ting out blood clots. She bled continuously for the next 3 hours, when she collapsed in her mother's car. She had concealed the extent of bleeding by swallowing much of the blood as she was keen to go to a party with her friends that evening. An ambulance was called. The crew removed the

stud, put pressure on the tongue, and commenced fluid resuscitation with 500 ml Gelofusine.

On arrival in accident & emergency the bleeding had stopped, her blood pressure was 82/41, pulse 88/min. A full blood count showed a haemoglobin of 11.0 g/dl. She was resuscitated with a further 500 ml Gelofusine and her cardio-vascular system stabilised.

Examination of the tongue revealed the site of piercing to be slightly to the left of the midline (Fig. 1).

The next day her haemoglobin was 10.5 g/dl with a blood pressure of 110/65 and a pulse of 74/minute. There was no bleeding dyscrasia. She was therefore discharged home on iron replacement therapy and antibiotic prophylaxis with amoxicillin and metronidazole.


Discussion

A variety of potential complications of oral piercing have been suggested (Table 1).⁴

Only five of these are potentially life-threatening (infection, disease transmission, airway obstruction, prolonged bleeding and aspiration). It is surprising that there has not been any reported case of prolonged bleeding secondary to tongue piercing, particularly bearing in mind the

Table 1 Potential complications of oral piercing

- Pain
- Oedema
- Infection
- Disease transmission
- Airway obstruction secondary to swelling
- Prolonged bleeding
- Chipped or fractured teeth
- Mucosal or gingival trauma
- Interference with mastication and swallowing
- Speech impediment
- Hypersalivation
- Hyperplastic or scar tissue formation
- Nerve damage and paraesthesia
- Aspiration of jewellery
- Foreign body incorporation into the site of piercing
- Obstruction of radiographic images
- Calculus formation on metal surfaces
- Metal hypersensitivity



¹Specialist Registrar, ²Visiting Specialist Registrar, ³Consultant, Department of Oral and Maxillofacial Surgery, Barts & The London NHS Trust, Whitechapel, London E1 1BB

Correspondence to: P. S. G. F. Hardee

REFEREED PAPER

Received 19.11.99; accepted 06.03.00

© British Dental Journal 2000; 188: 657-658

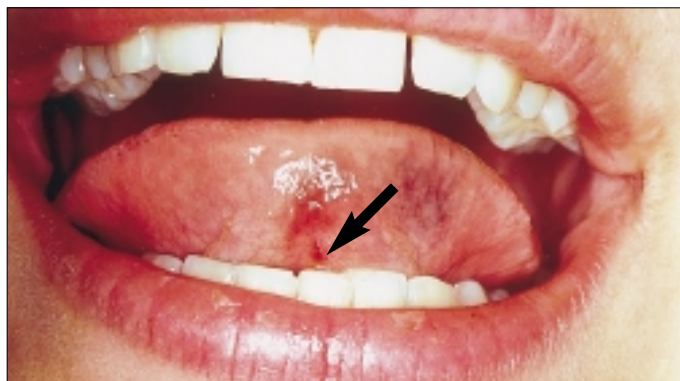
thickness of the tongue, its vascularity, and the potential for tearing a vessel during the piercing process.

Although it is difficult to make a precise estimate of the blood loss in this patient, young fit adults are very resistant to the effects of acute blood loss. It is likely that this patient, who had previously been fit and well, had a pre-piercing haemoglobin in the normal range for females (11.5–16.5 g/dl). Following haemodilution her haemoglobin was 10.5 g/dl. Therefore the combination of her clinical circulatory collapse and these figures suggest a significant acute loss of blood during the post-piercing haemorrhage. She had not been given any instructions on what to do should the tongue continue to bleed. Fortunately, her collapse was observed and appropriate action was taken in removing the barbell and placing local pressure.

Following our experience with the patient we telephoned all body piercing studios advertising in the *Yellow Pages* for central London and asked what advice they would give for looking after the tongue following piercing. They all mentioned the risk of swelling, recommended sucking ice cubes and emphasised the use of antibacterial (or hot salt water) mouthwashes after eating, drinking or smoking. Presumably, this was triggered by the report of Ludwig's angina.³ None of them gave any advice on simple measures to control bleeding.

This report of a further significant complication of tongue piercing reinforces the concern that has been previously

Fig 1. Site of tongue piercing shown by arrow (note also surrounding bruising)



expressed regarding the practice of tongue piercing.^{2,3}

The practice of body piercing will continue. Fortunately, few people have problems related to this. However, in the light of our experience and that of other clinicians, we would recommend that government introduces legislation to licence all piercing establishments because of the potential dangers. Furthermore, we recommend that all piercing establishments hand out written advice on potential dangers and how to cope with these, including the management of haemorrhage. We would suggest the following:

- Reduce the risk of swelling by sucking ice cubes hourly for the rest of the day
- If your tongue swells, making it difficult to swallow or breathe, go directly to the nearest casualty department
- Reduce the risk of infection by using hot salt water mouthbaths 4-hourly, and after eating (use 1 teaspoon of salt in one glass

of hot water, hold over affected site for at least 2 minutes)

- If the area around the jewellery becomes red and tender, it may be becoming infected. Go to your family doctor or a casualty department
- If part of the jewellery becomes dislodged and you may have swallowed or inhaled it, go to your nearest casualty department
- If the piercing site bleeds, compress it firmly with clean linen (eg handkerchief) for up to 30 minutes
- If the bleeding does not stop, go immediately to casualty, and ask to be referred to the maxillofacial surgeon.

- 1 Healey T. Nipple piercings: unusual artefacts. *Radiography* 1979; 45: 164-165.
- 2 Chen M, Scully C. Tongue piercing — a new fad in body art. *Br Dent J* 1992; 172: 87.
- 3 Perkins C S, Harrison J M. A complication of tongue piercing. *Br Dent J* 1997; 182: 147-148.
- 4 Farah C S, Harmon D M. Tongue piercing: case report and review of current practice. *Aust Dent J* 1998; 43: 387-389.

Submitting illustrations to the BDJ

Authors submitting manuscripts for publication in the BDJ are reminded that two copies of all illustrations must be supplied. This will assist in speeding up the refereeing process — manuscripts and illustrations are always sent to referees and a set of illustrations is required at the editorial office for reference. If you choose to submit 35-mm transparencies then one set of these and one set of prints (colour or black & white) will be acceptable.

We strongly advise authors to keep copies of all illustrations submitted in case letters are lost or damaged in transit. Please do not send glass-mounted transparencies — even when securely wrapped the glass will often arrive cracked or shattered, resulting in damage to the surface of the slide which usually renders it unsuitable for reproduction.

